

# *Common Procedures in ER*

**Maede Asna Ashari , MD**

Assistant Professor of Emergency Medicine

**EMERGENCY**

**Basic Airway Management**

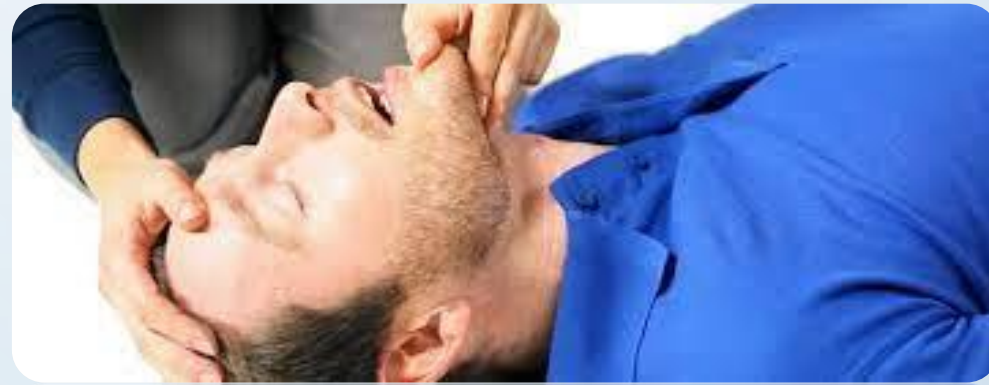**Arterial Puncture**

**Nasogastric Tube**

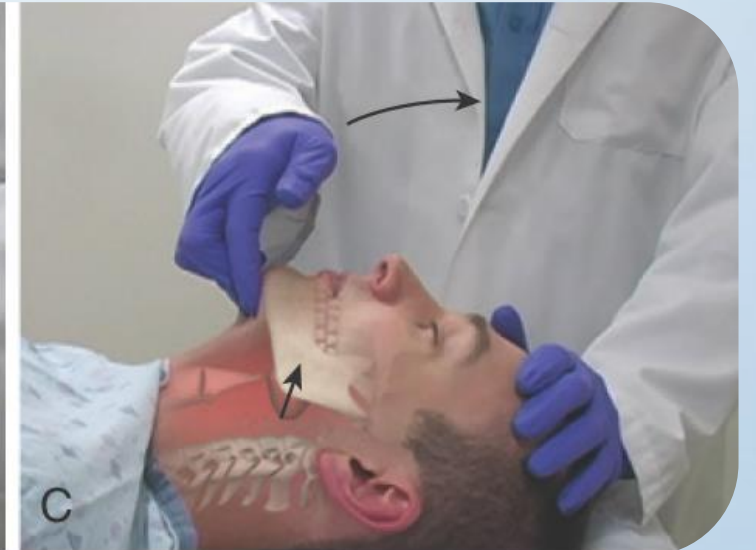
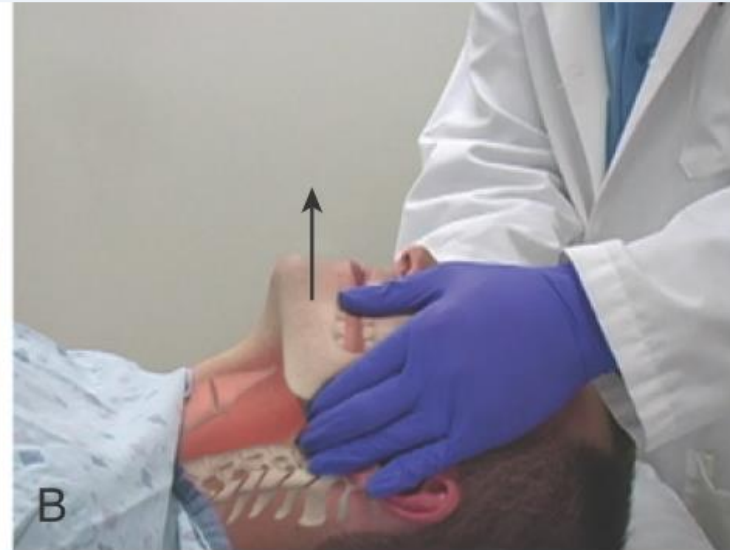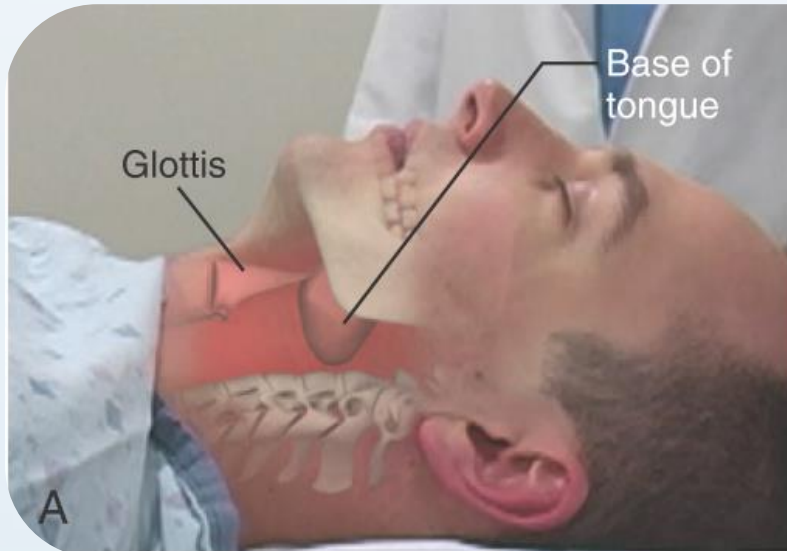
**Foley Catheter**

**Wound Management**

# Basic Airway Management



# Manual Airway Maneuvers

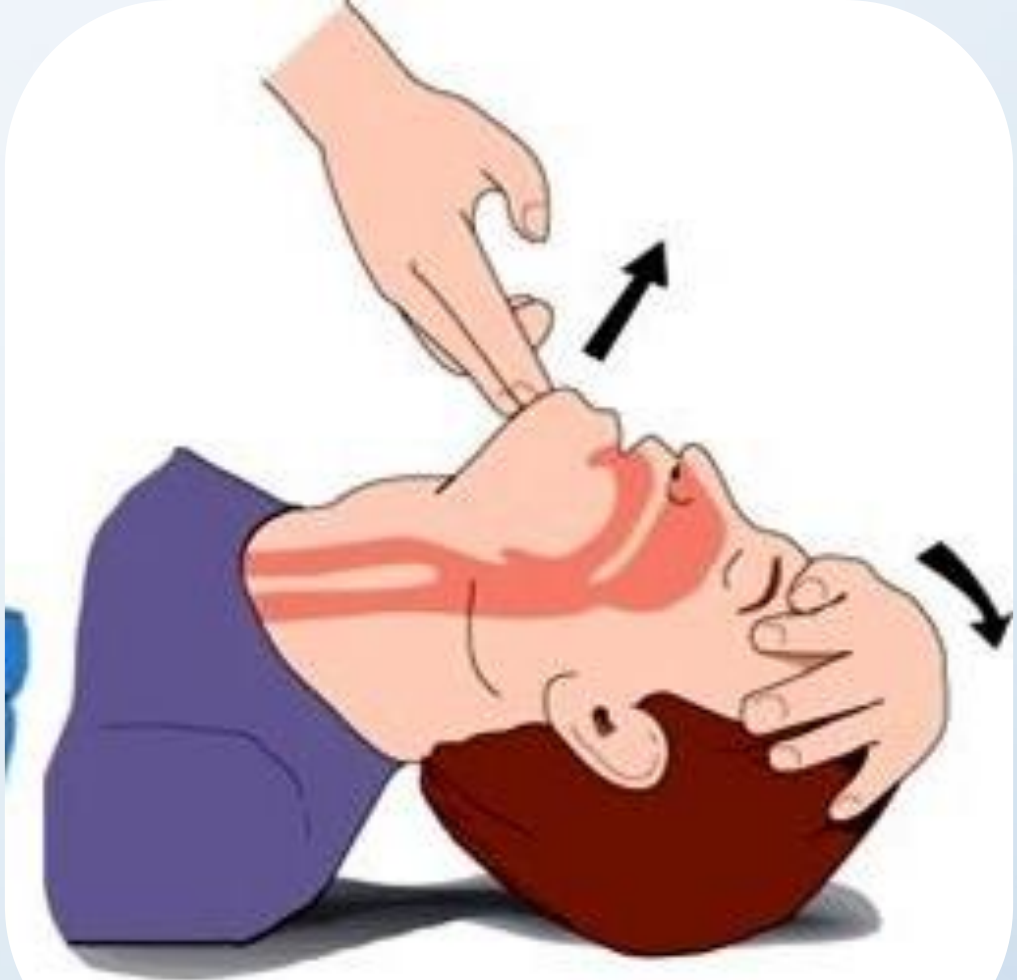

Common cause of The most airway obstruction in an unconscious patient is tongue

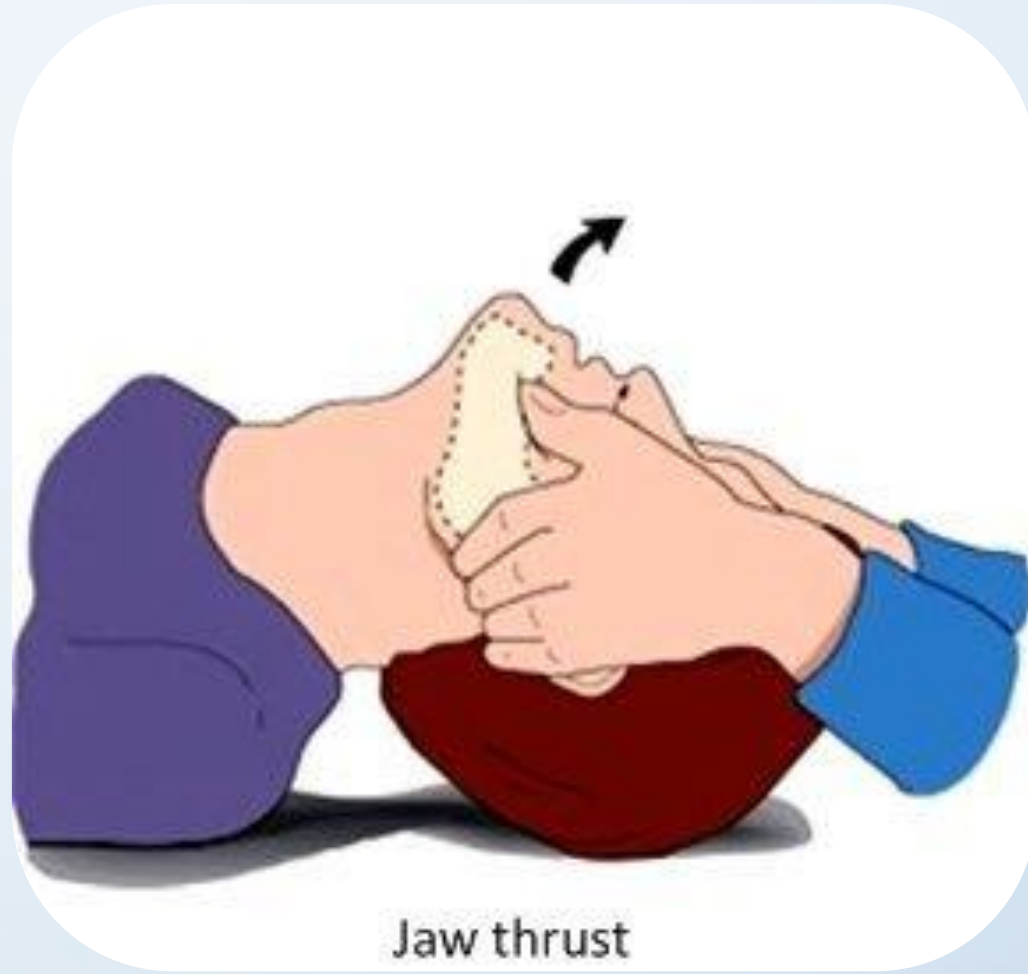Head tilt/chin lift

Jaw thrust





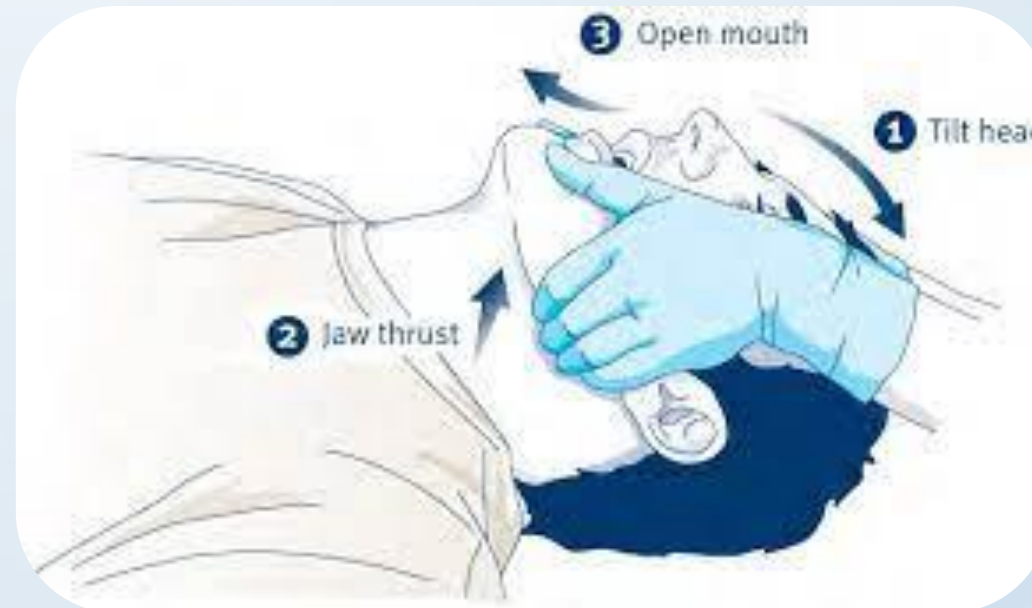
Chin lift



Jaw thrust

# The Triple Airway Maneuver

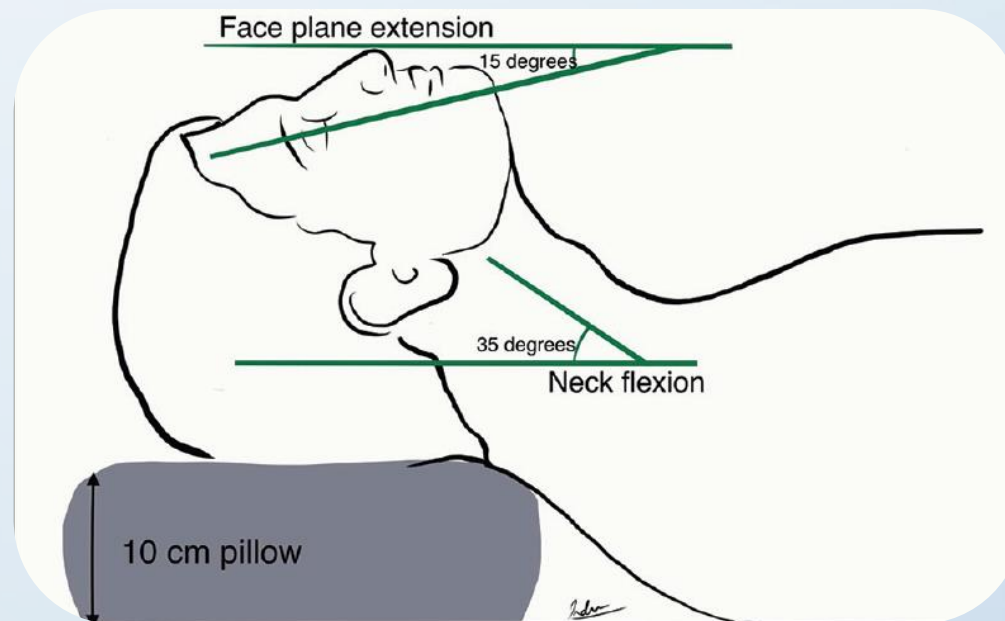
*Head tilt+ jaw thrust+ mouth opening*




# Patient Positioning

## Sniffing position

The neck is flexed relative to the torso and with atlanto-occipital extension





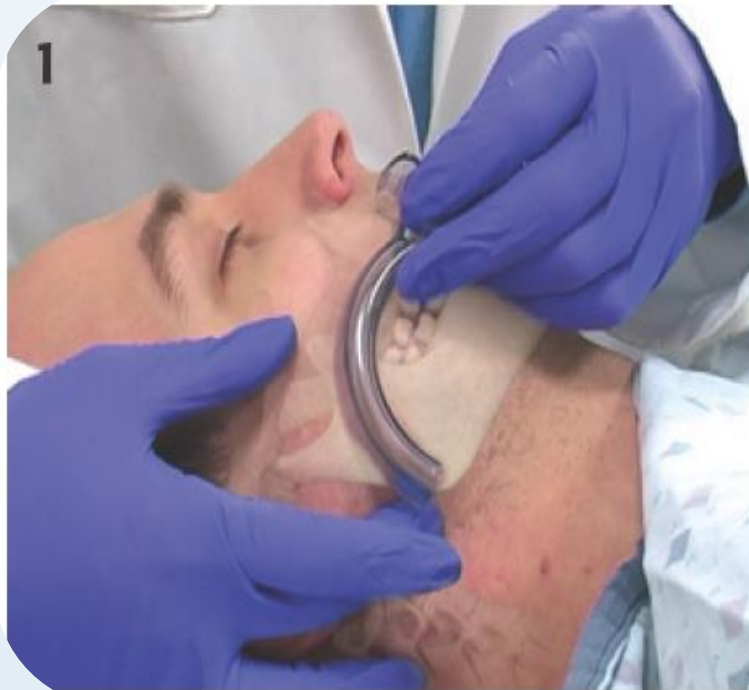

The best position for opening the upper airway in morbidly obese patients is **elevation of the head, neck, and shoulders so that the external auditory meatus is aligned with the sternum**

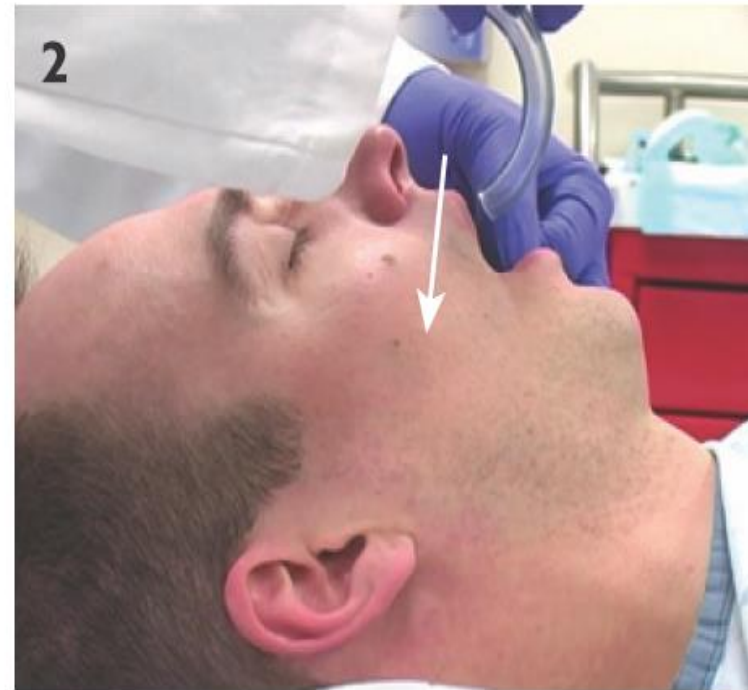# Oropharyngeal Airway Insertion Equipment



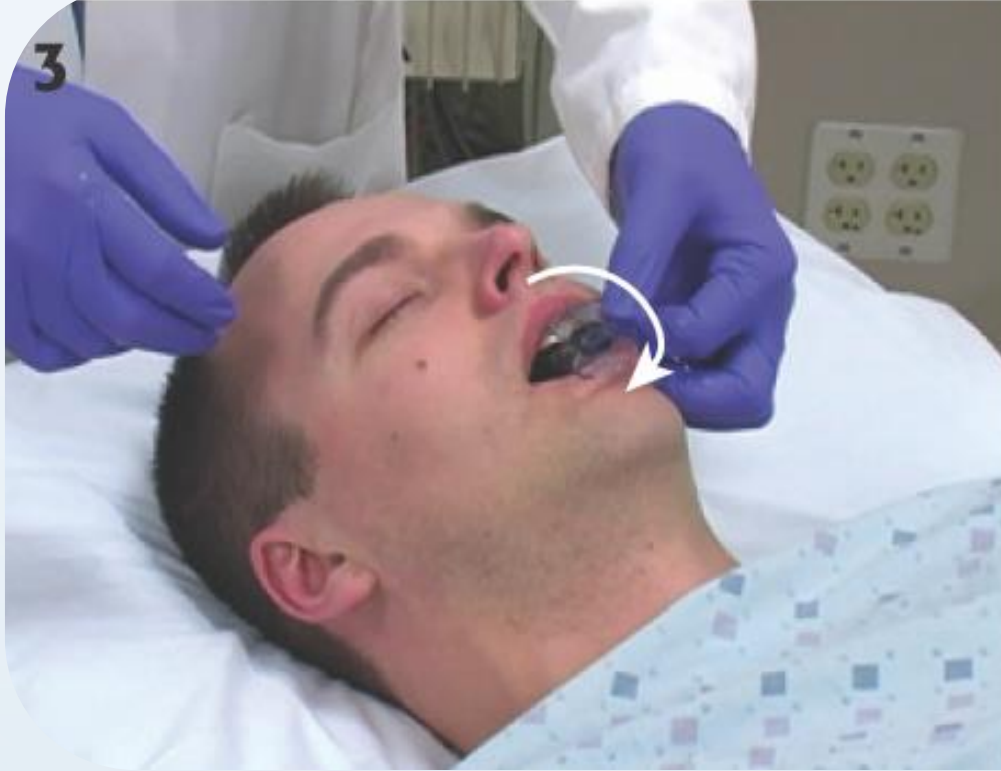# Oropharyngeal Airway Insertion



For oropharyngeal airway insertion, first measure. An airway of correct size will extend from the corner of the mouth to the earlobe or the angle of the mandible.

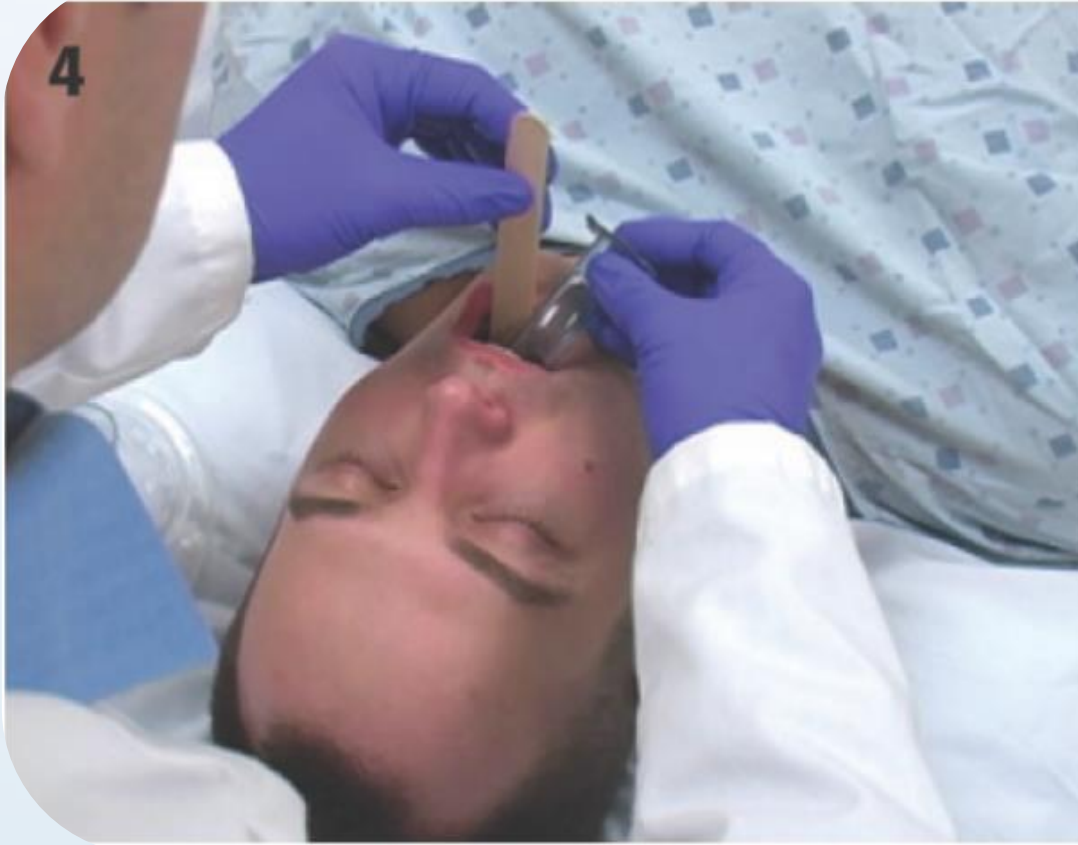

Open the patient's mouth with your thumb and index finger, then insert the airway in an inverted position along the patient's hard palate.



When the airway is well into the mouth, rotate it 180°, with the distal end of the airway lying in the hypopharynx. It may help to pull the jaw forward during passage.

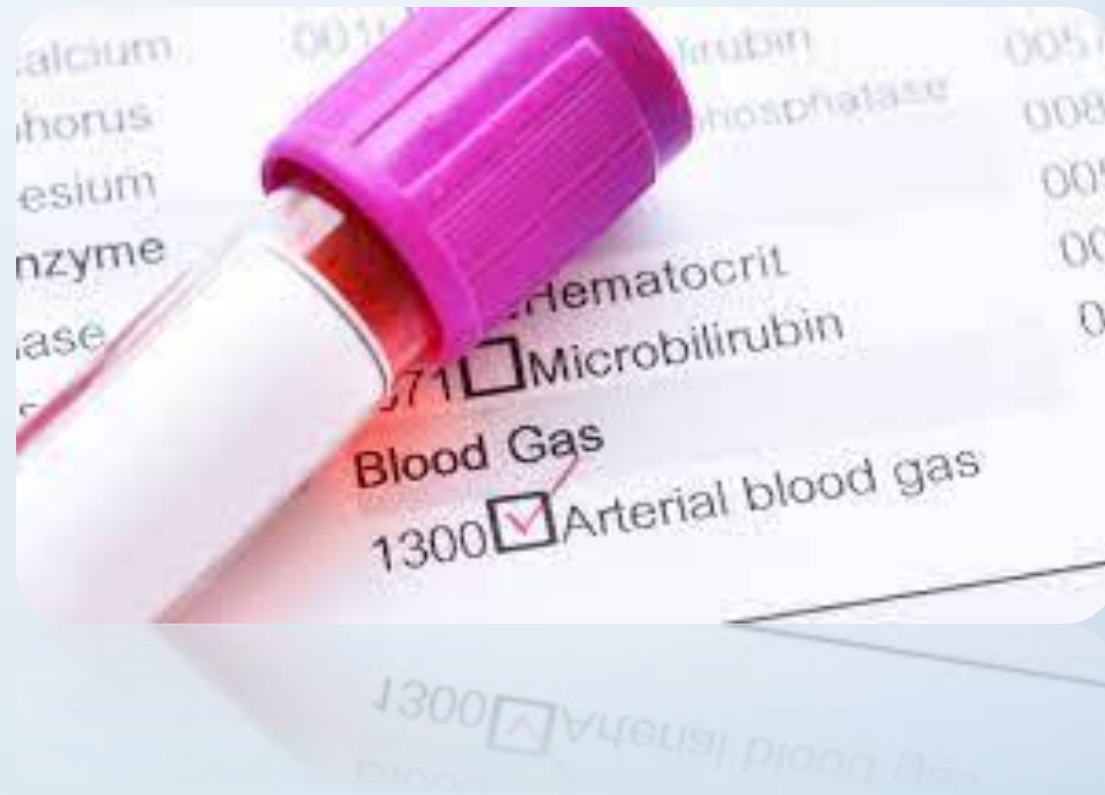



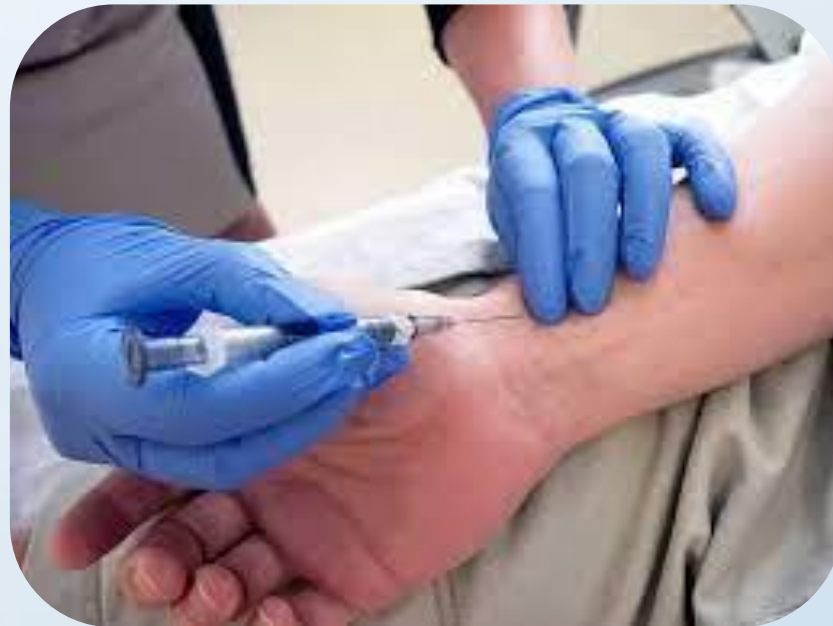Alternatively, open the mouth widely and use a tongue blade to displace the tongue inferiorly, and advance the airway into the oropharynx. No rotation is required with this method.



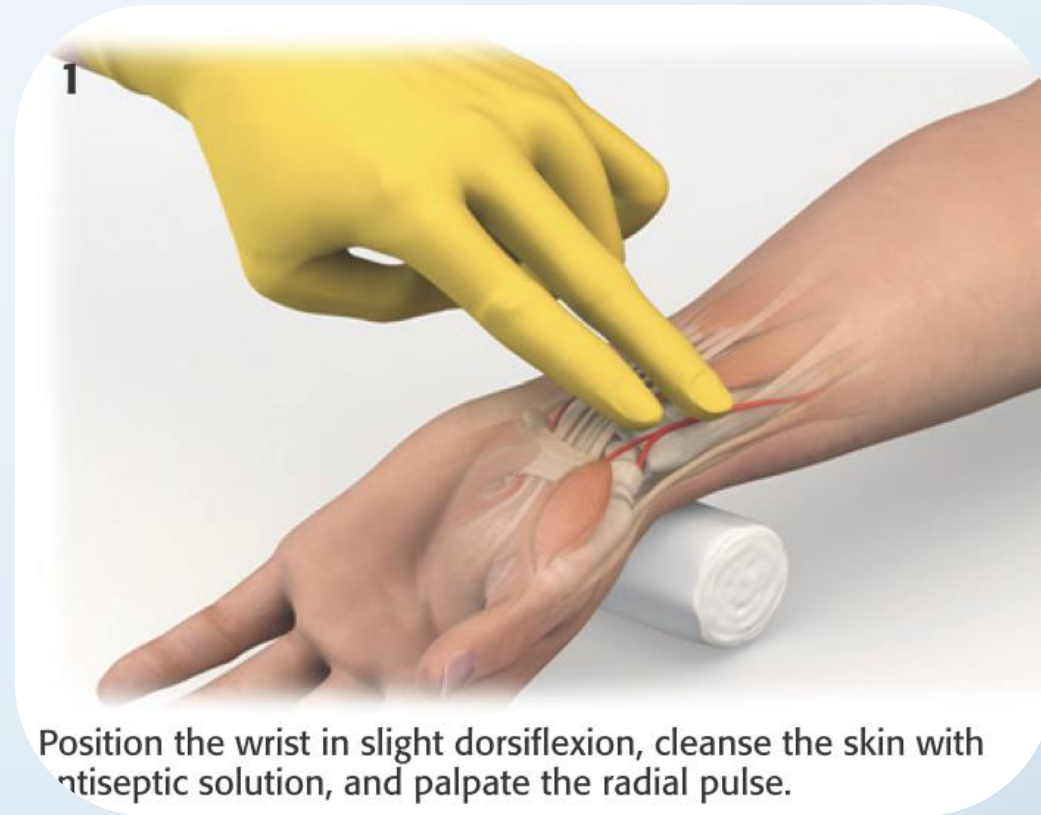# Arterial Puncture



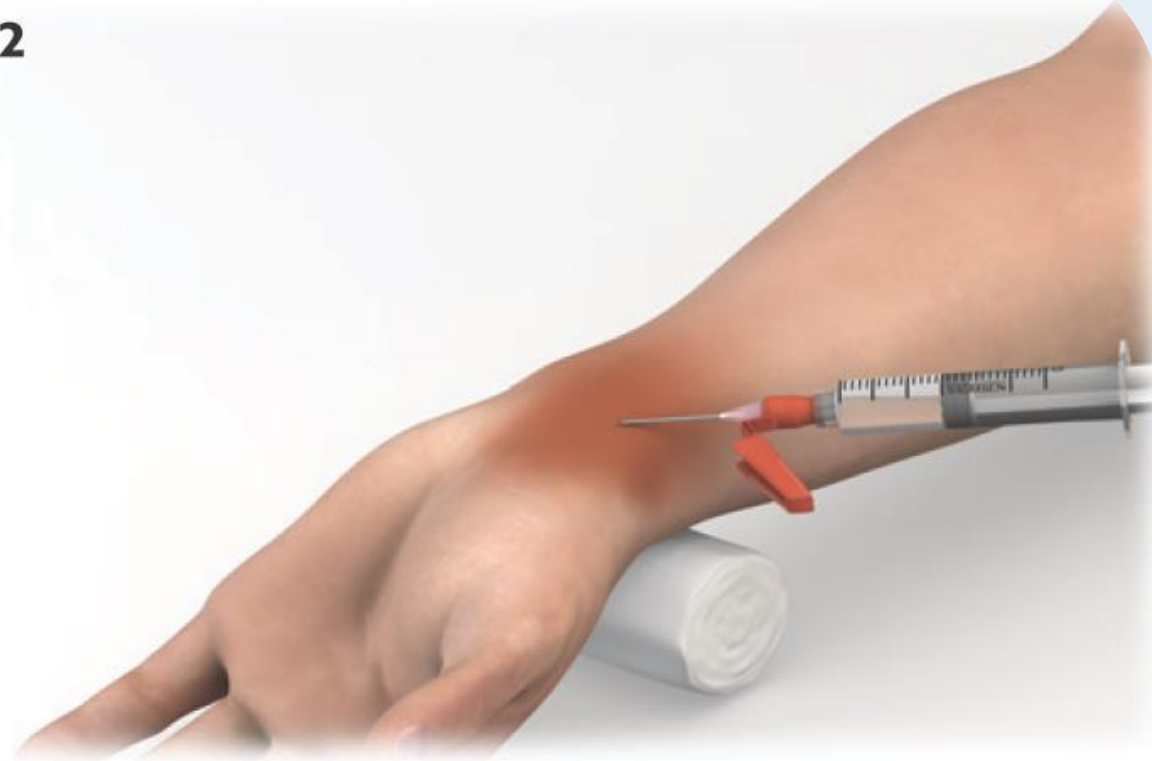
The **radial, brachial, and femoral arteries** are the sites usually punctured for blood gas sampling in adults



# Arterial Puncture (Radial Artery)

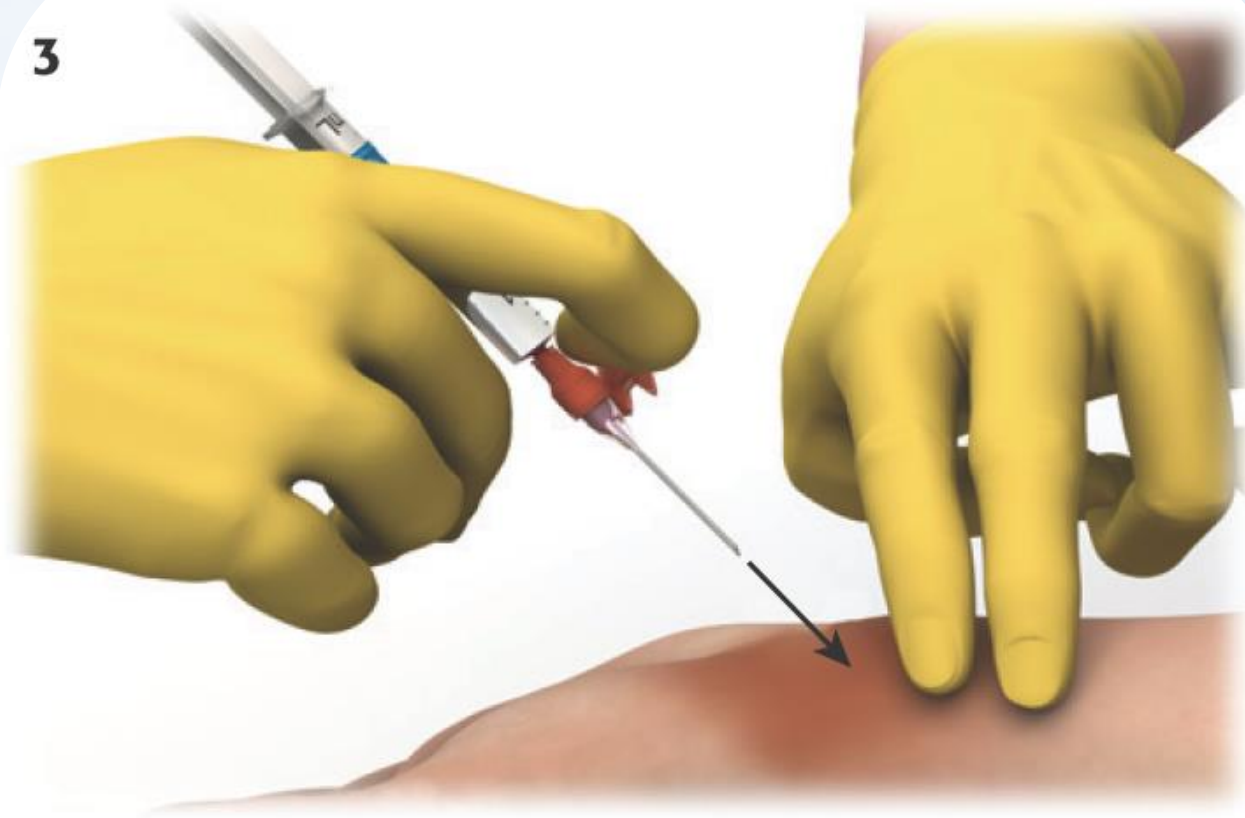

2



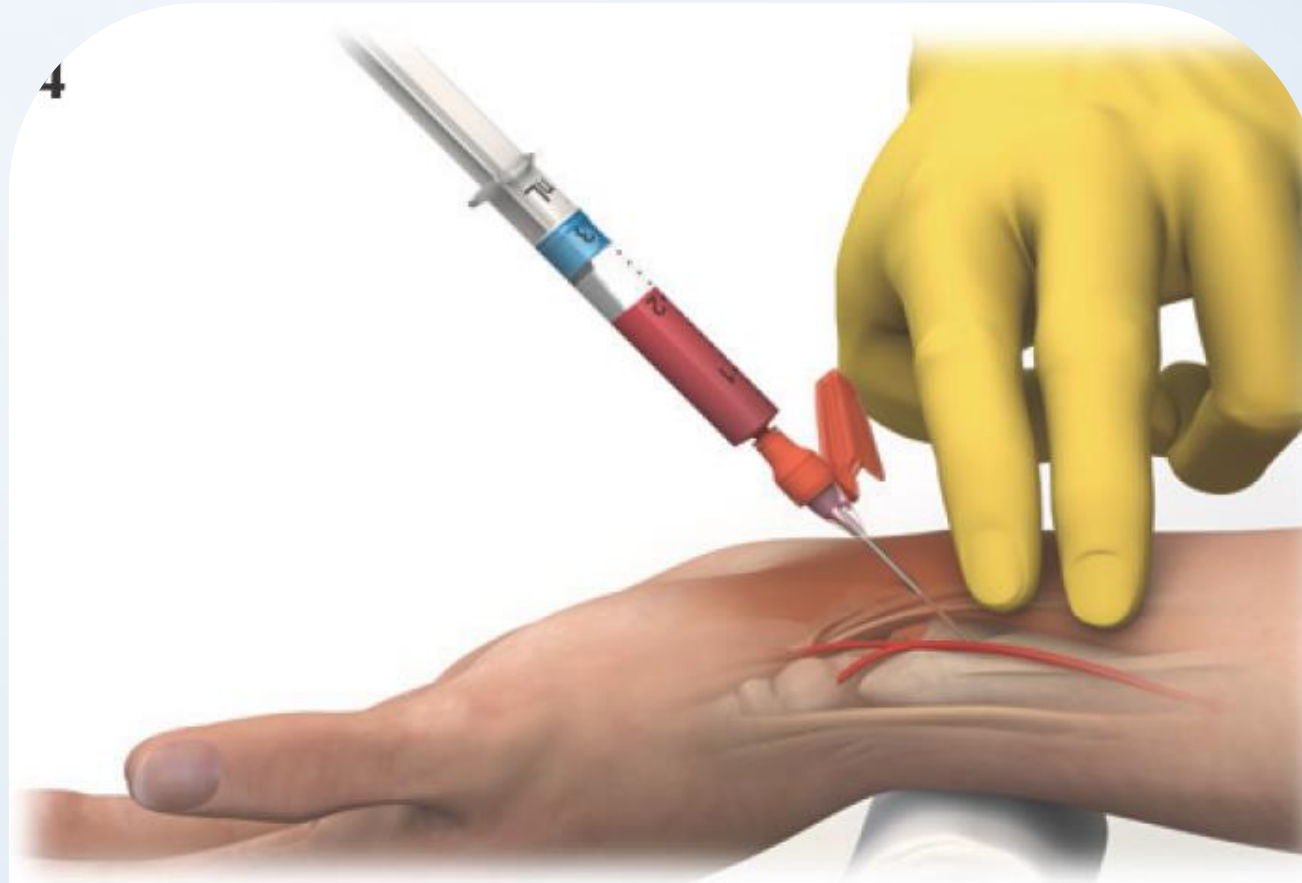
Optionally, place a small wheal of local anesthetic (e.g., 1% lidocaine without epinephrine) over the entry site. Avoid placing a wheal that is too large of a wheal, which may obscure the artery.

3



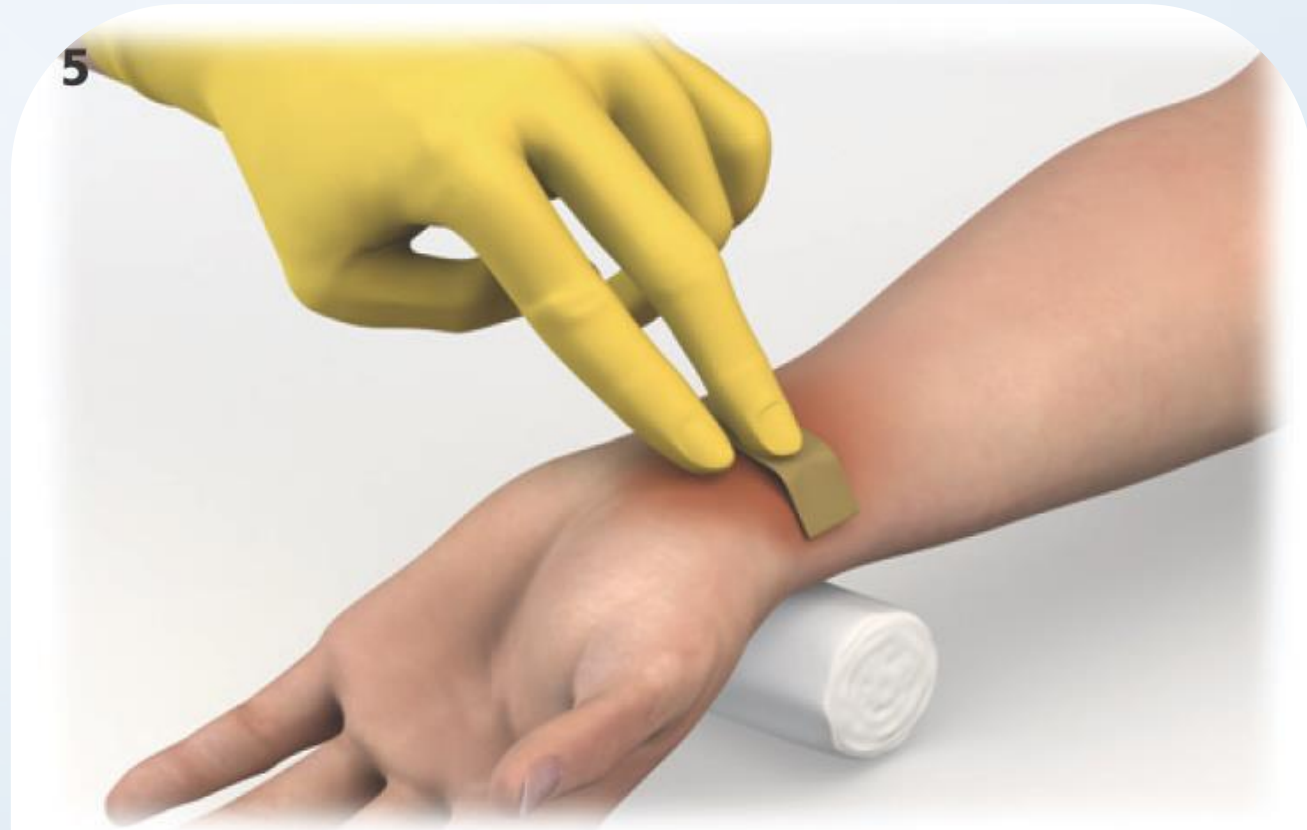Hold the syringe in your hand like a dart, with the bevel up. Palpate the artery with the index and middle fingers of your other hand. Puncture the skin distal to your finger, and slowly advance needle at a 30° angle toward the pulsating vessel.





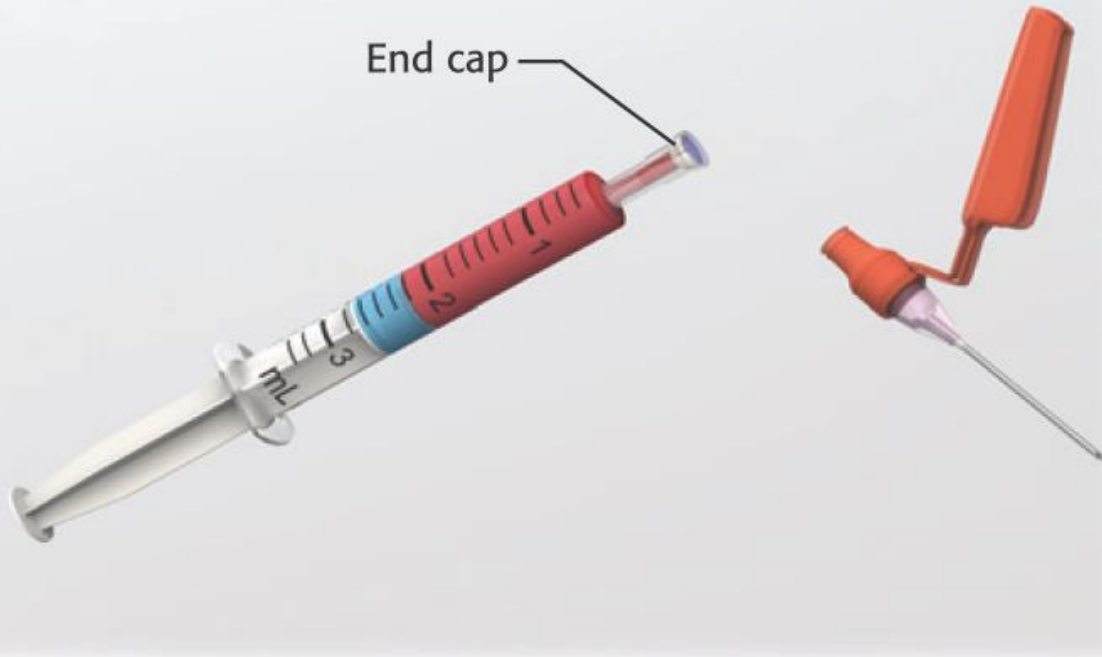
4

As soon as blood flows, stop advancing the needle. Allow the syringe to fill on its own. If bone is encountered, withdraw slowly because both vessel walls may have been penetrated and the lumen may be entered as the needle is withdrawn.



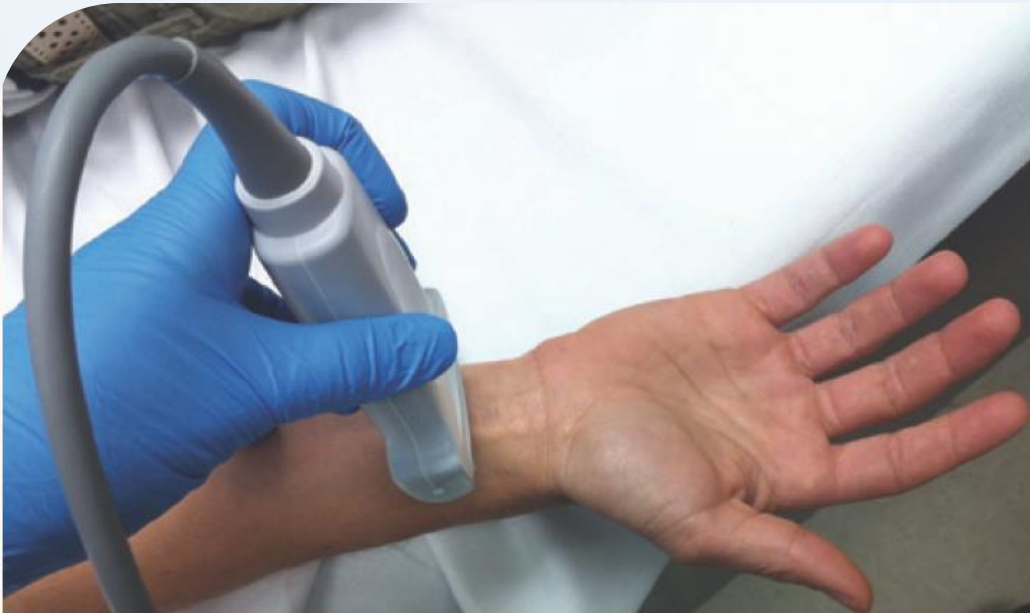5 Remove the needle from the artery after the syringe has filled. Apply a bandage and firm pressure to the puncture site for a minimum of 3 to 5 minutes.

6

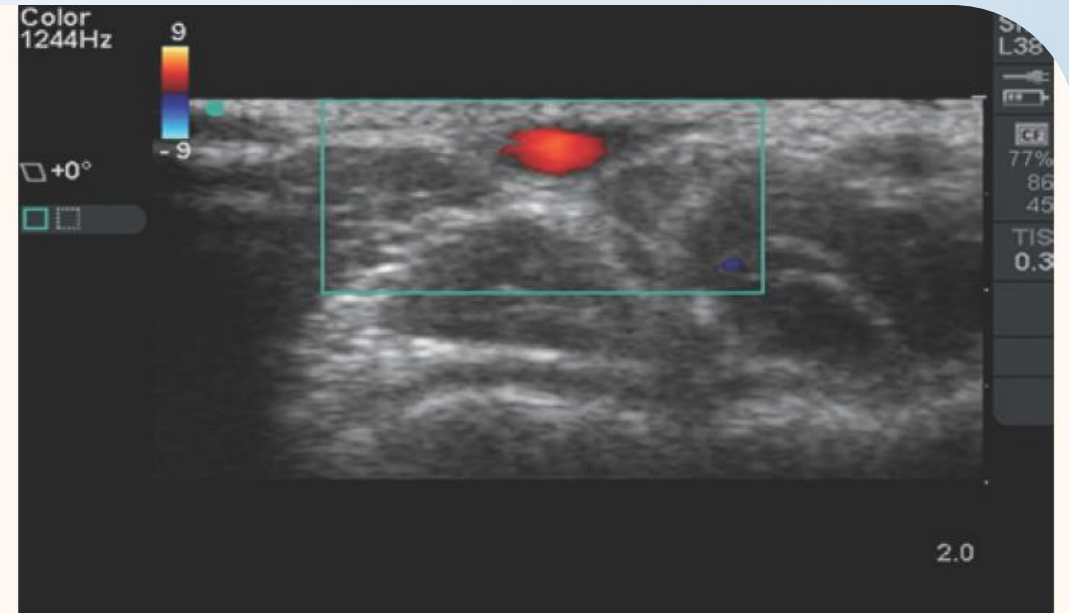


Remove all air from the syringe by holding it upward, gently tapping it, and depressing the plunger. Attach the end cap to the syringe to maintain anaerobic conditions, and submit the sample to the laboratory.

# ABG with the use of ultrasound



**Figure 20.US1** Placement of the transducer over the distal end of the arm in the transverse plane to localize the radial artery.



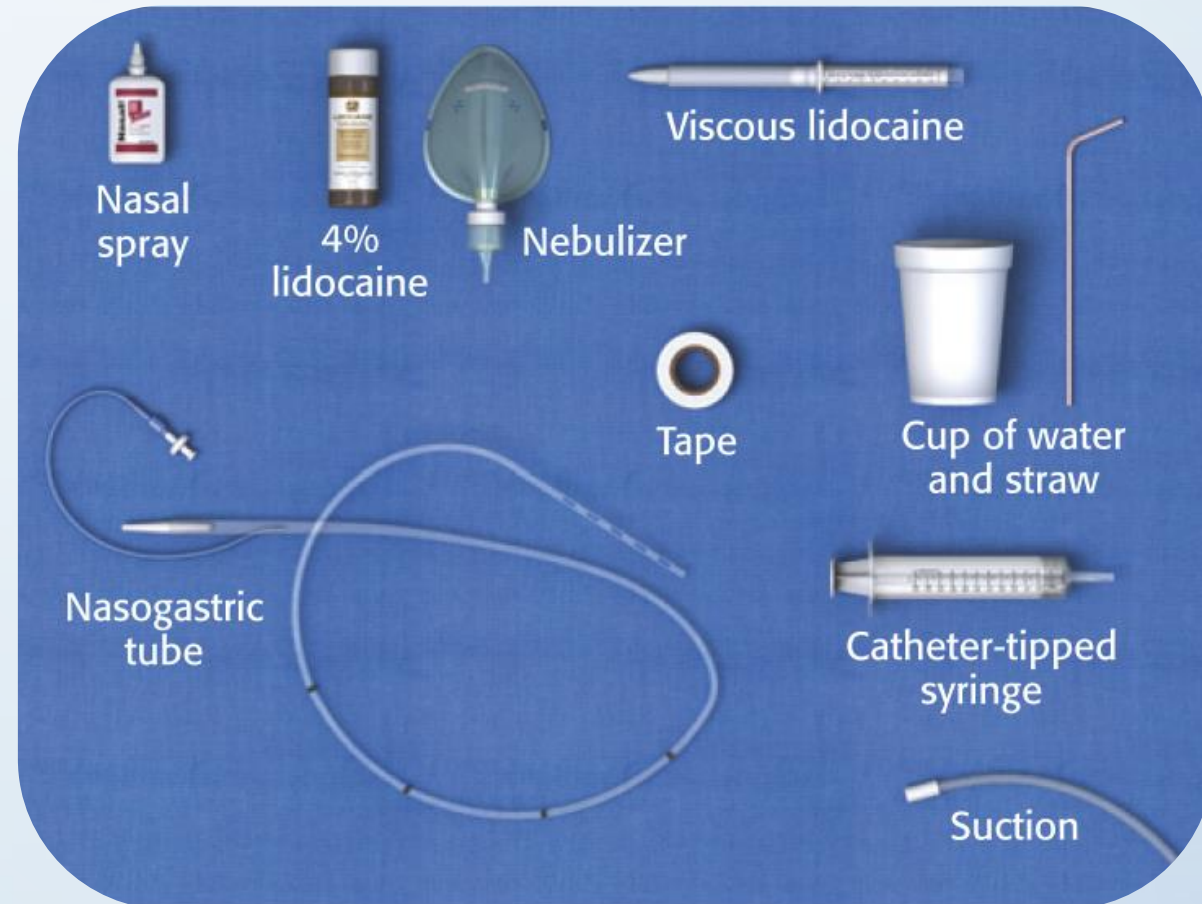
**Figure 20.US2** Image of the radial artery with color flow. Applying color flow will enable the operator to correctly identify the artery.

# Nasogastric Tube

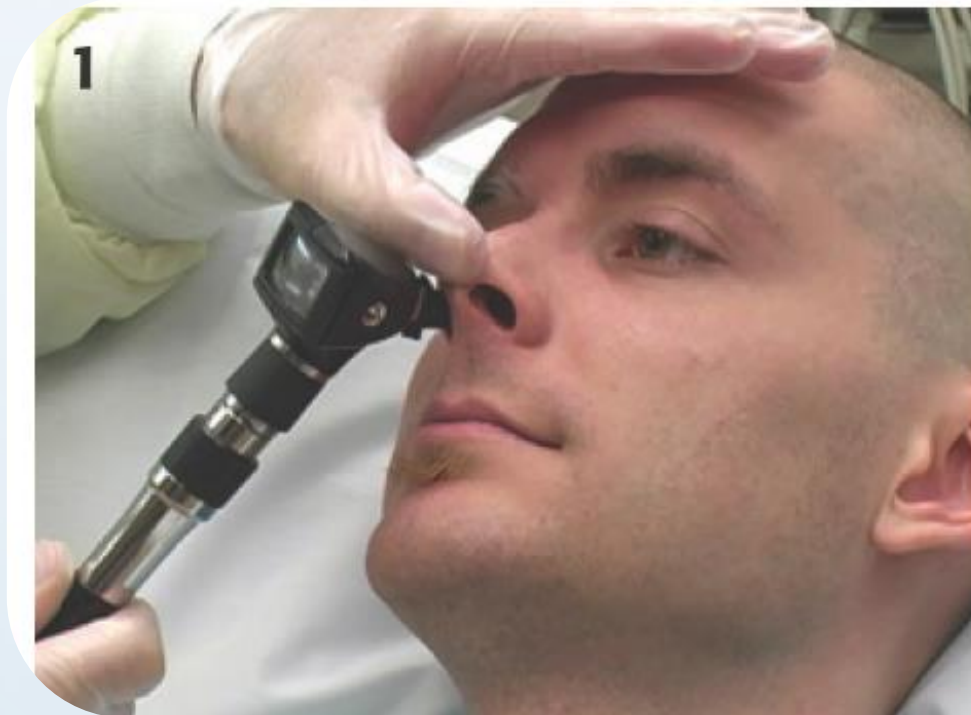



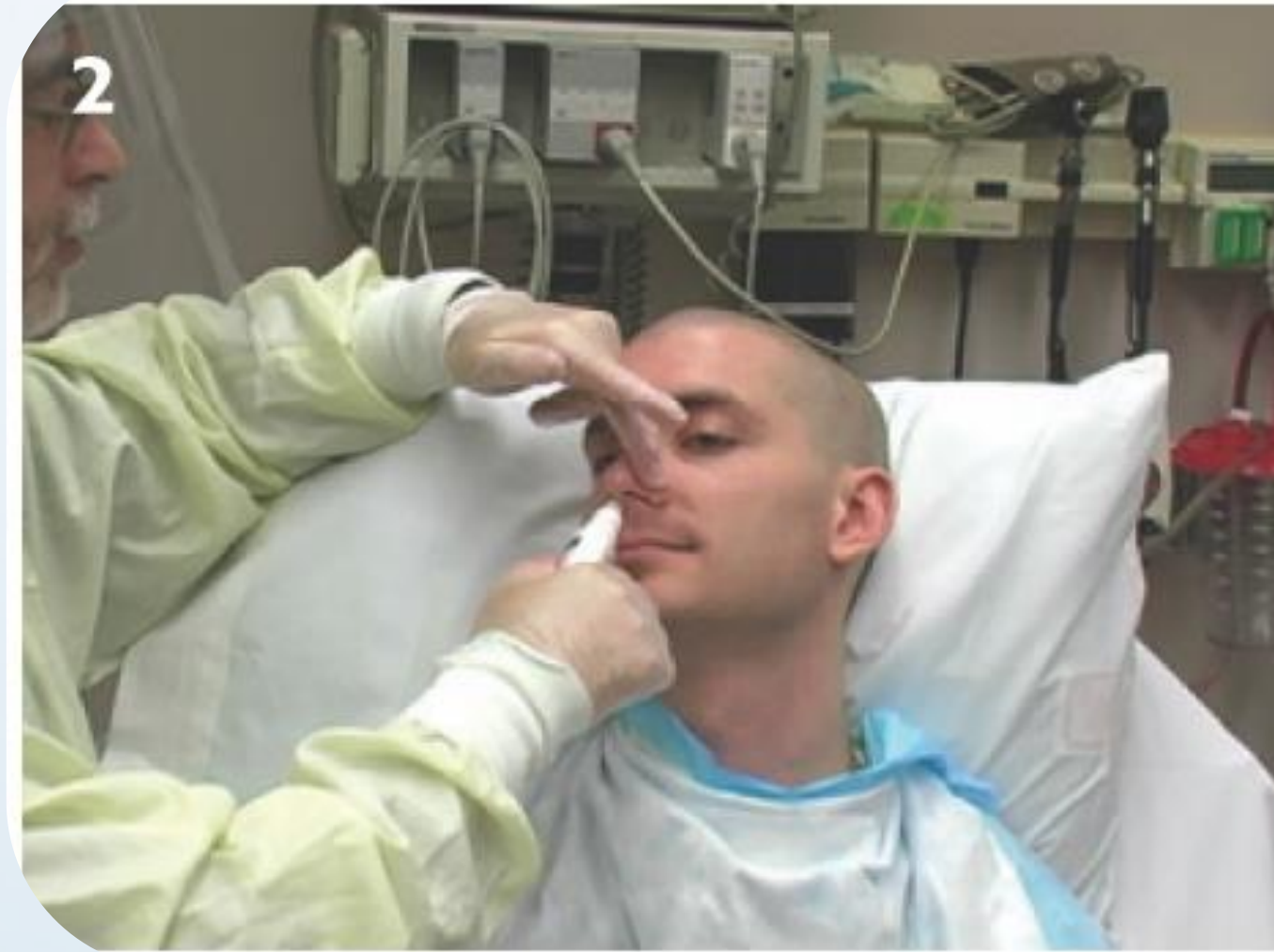
# Equipment



# Nasogastric Tube Placement

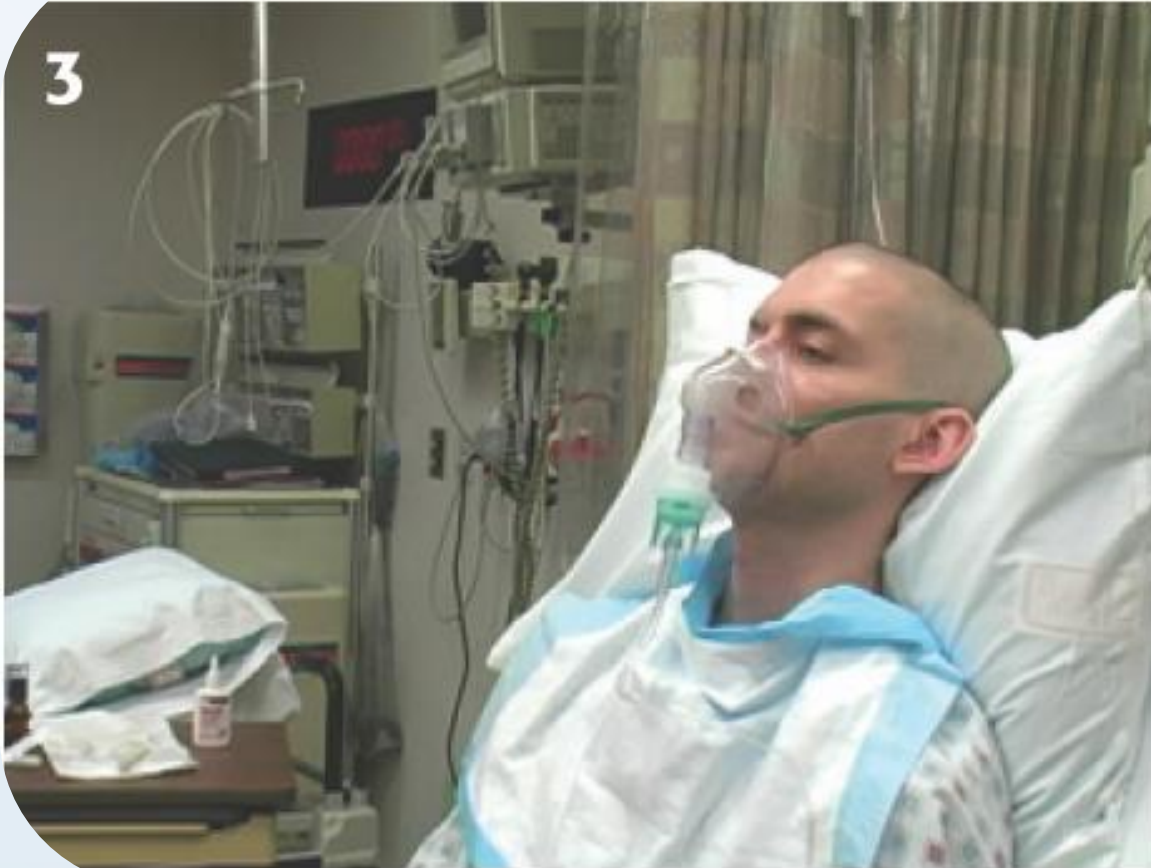

Choose the most patent naris by visual inspection and the sniff test. Alternatively, insert a gloved finger into each nostril to assess patency.



Apply a topical vasoconstrictor, such as phenylephrine or oxymetazoline.

3

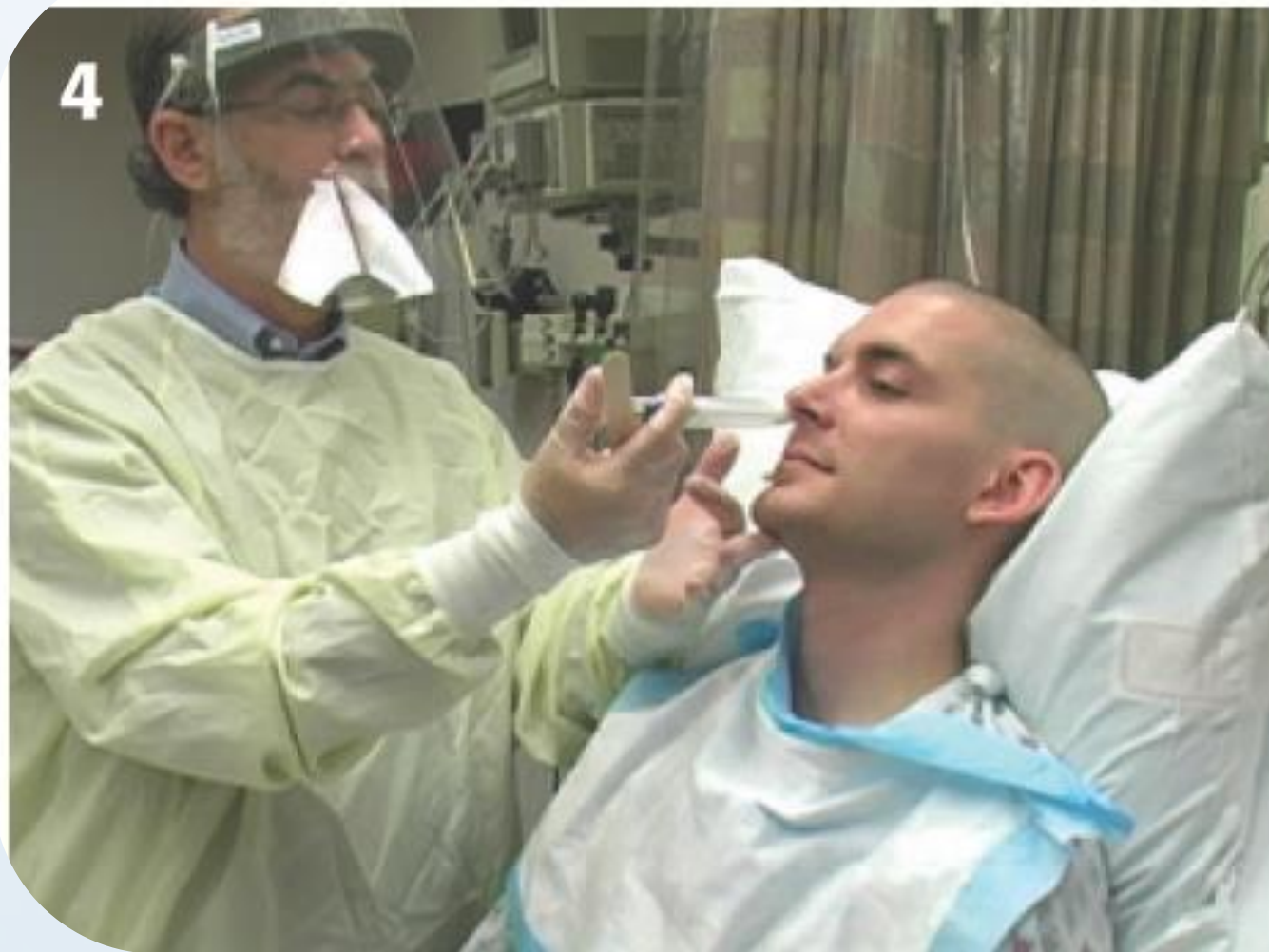

Anesthetize the naris, nasopharynx, and oropharynx at least 5 minutes before the procedure.

Nebulized lidocaine is ideal because it reduces both nasal and pharyngeal discomfort.



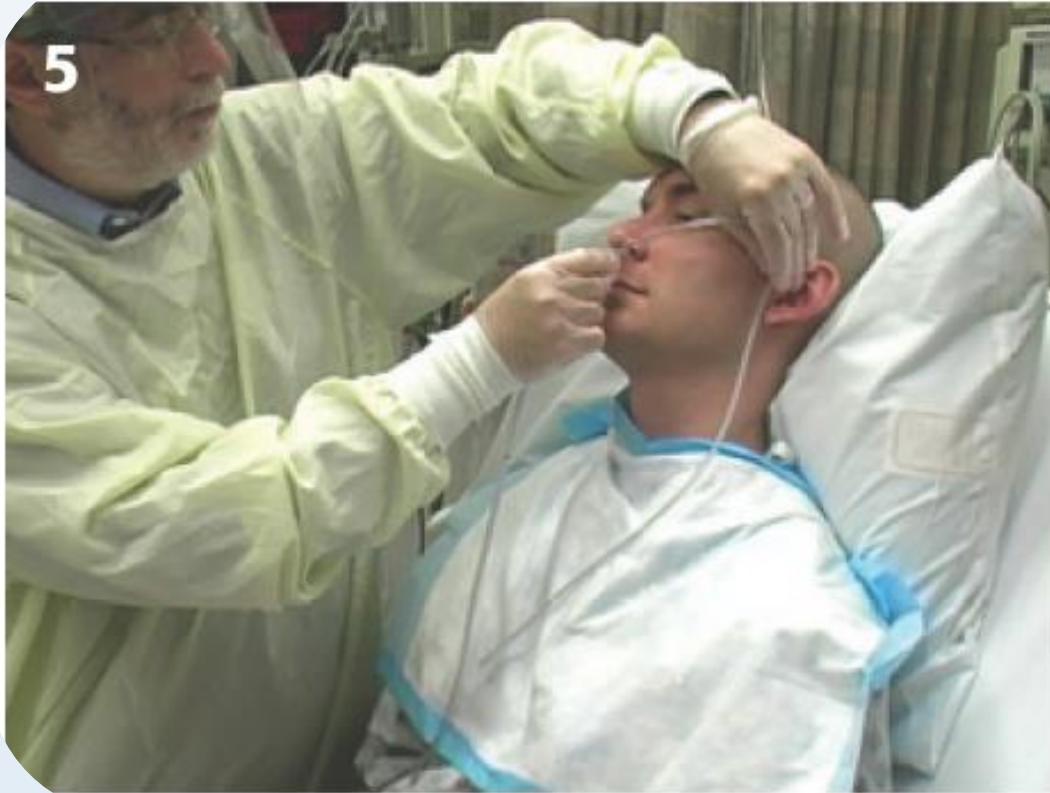4



Apply 2% viscous lidocaine along the floor of the nasal cavity, and allow it to drip into the nasopharynx and be swallowed.



5

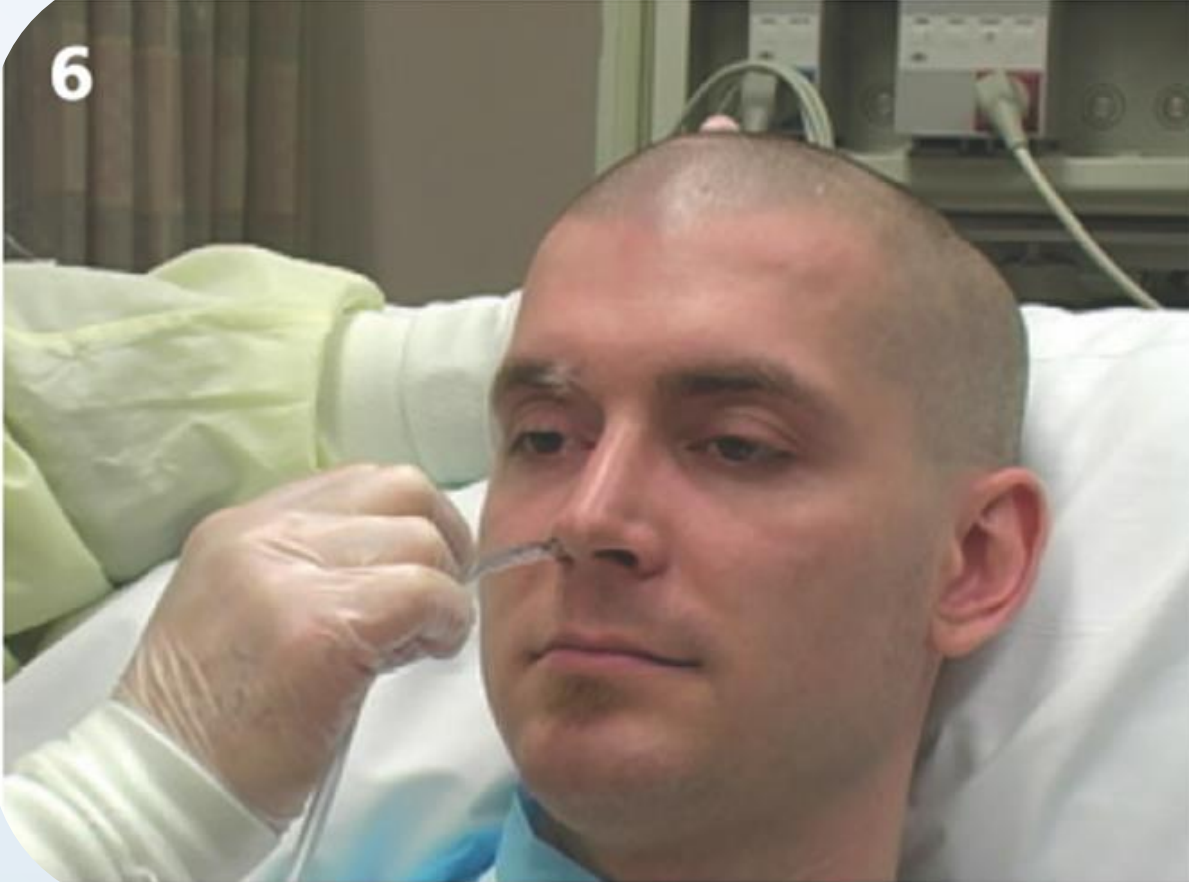

Measure the distance from the tip of the nose to the earlobe to the xiphoid process.

Add another 15 cm to this distance.

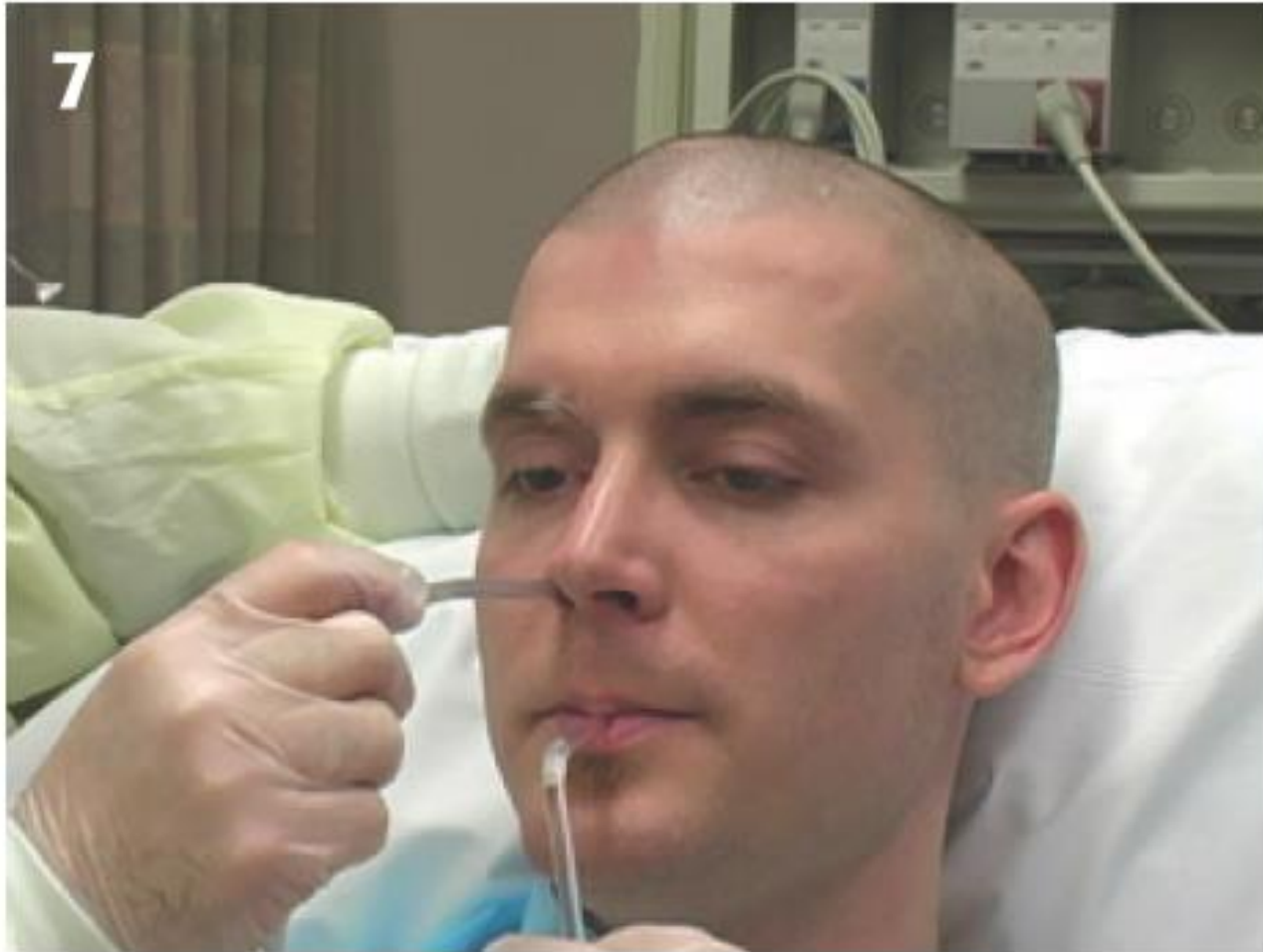Note the total distance on the nasogastric tube markers.

6



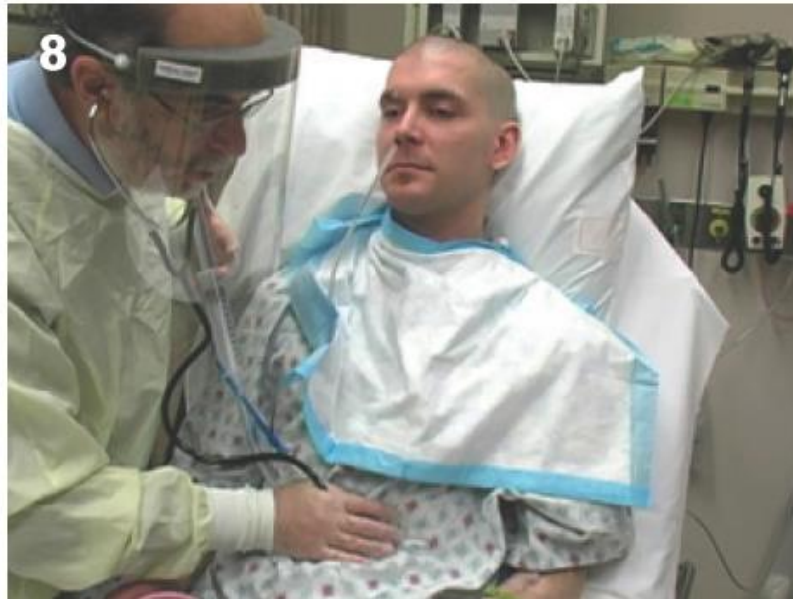Slowly insert the nasogastric tube along the floor of the nostril under direct vision until it passes into the oropharynx.

7

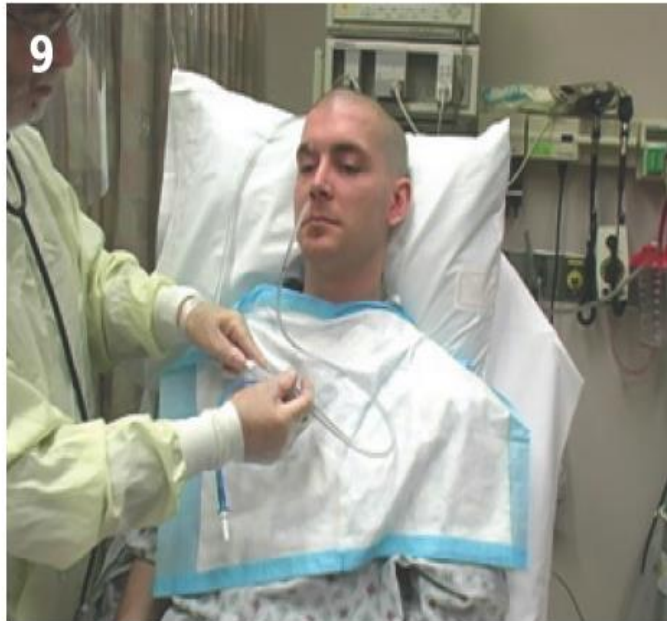

While the patient sips water from a straw, rapidly pass the tube to the predetermined depth. Coordinate tube advancement with the swallowing mechanism to promote easy passage.

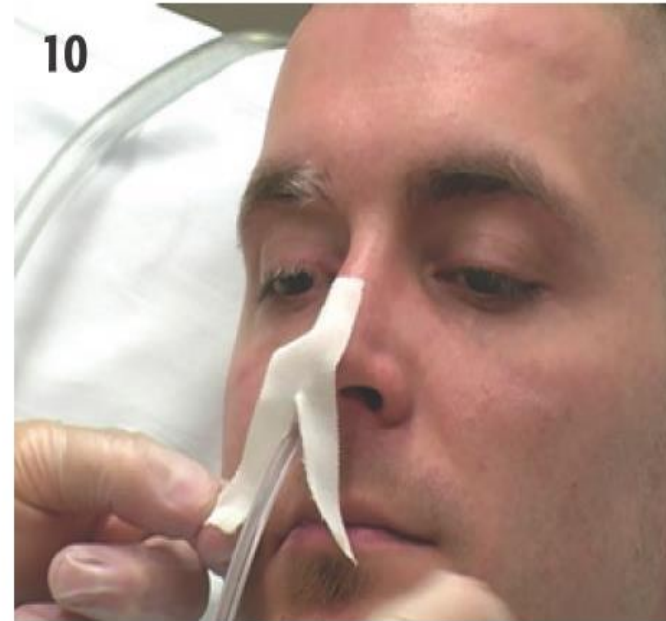



Assess tube placement with air insufflation and aspiration.

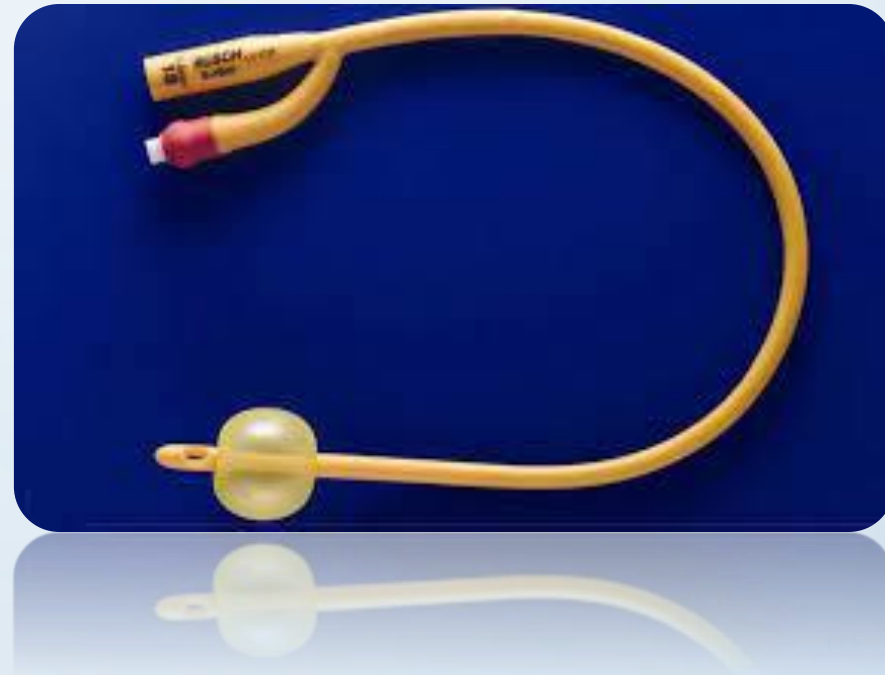

Attach the tube to intermittent wall suction.



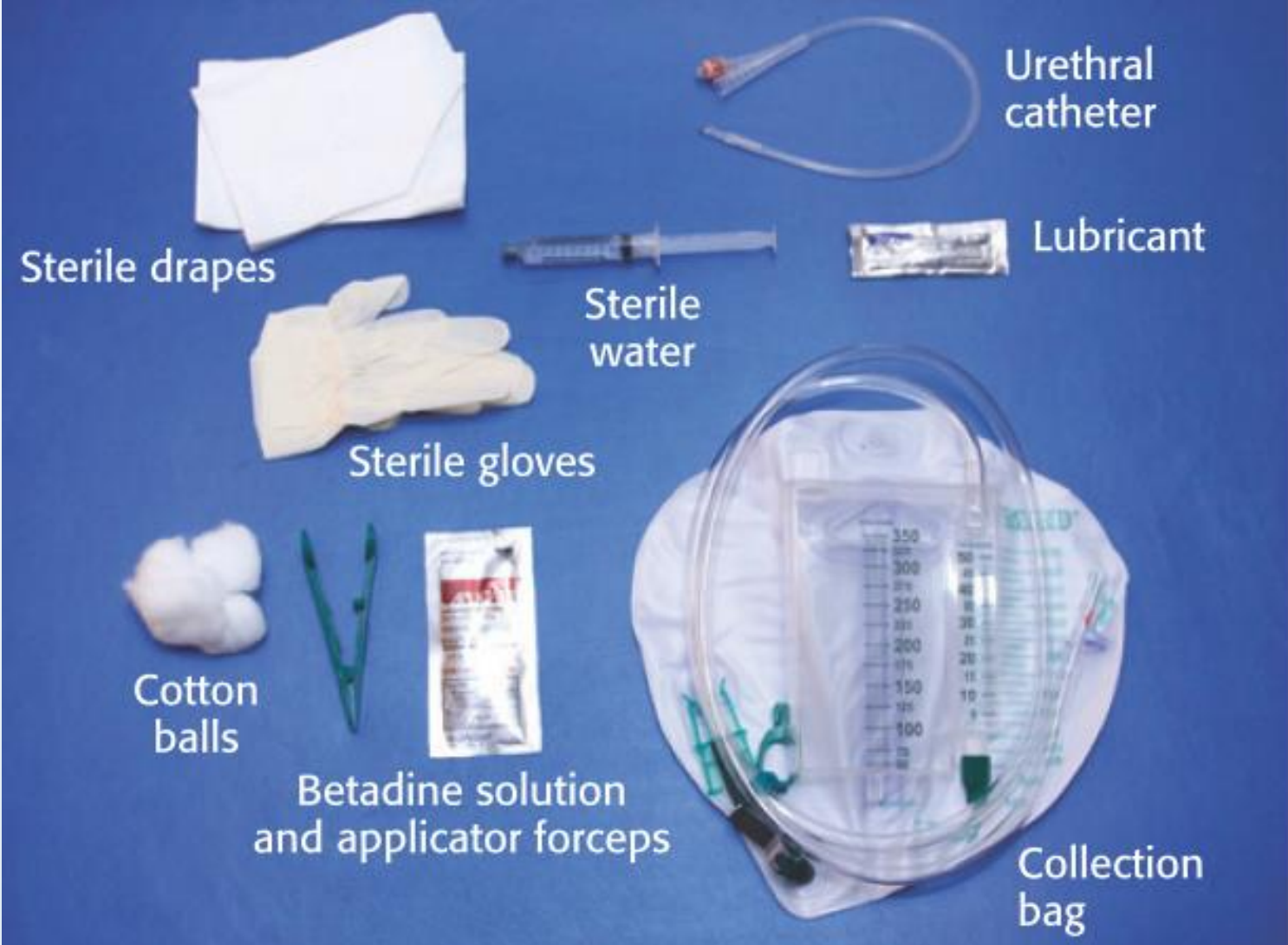Secure the tube to the nose with tape.

# Foley Catheter



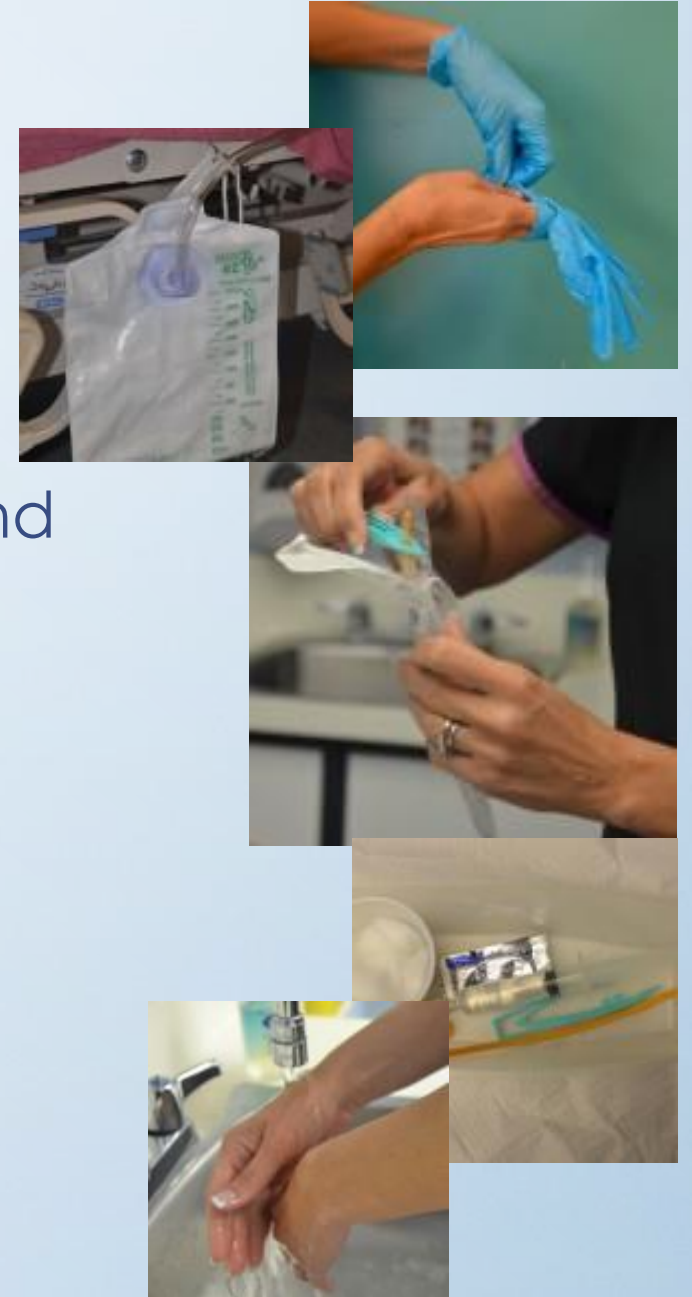


# Equipment

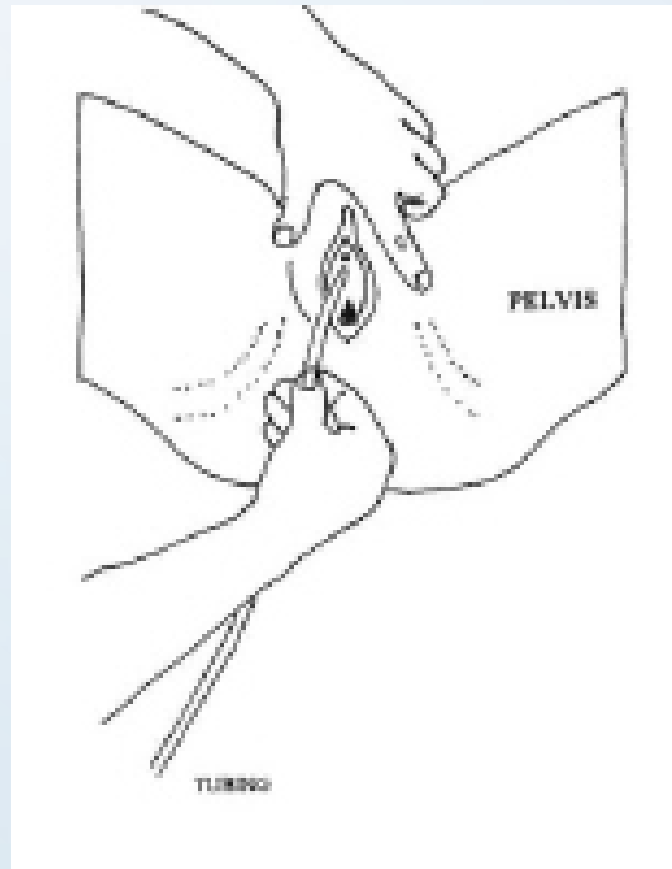


# Procedure

- Gather equipment
- Explain procedure to the patient
- Assist patient into supine position with legs spread and feet together
- Open catheterization kit and catheter
- Prepare sterile field, apply sterile gloves
- Wash your hands
- Check balloon for patency
- Generously coat the distal portion (2-5 cm) of the catheter with lubricant

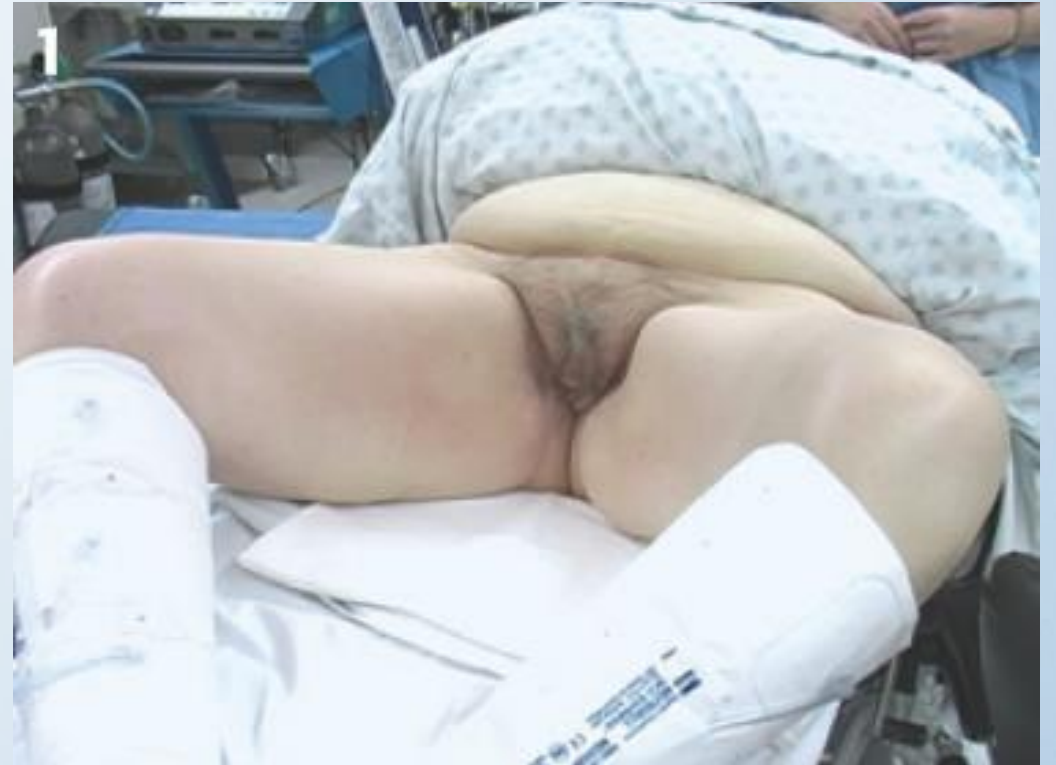

# Female Catheterization

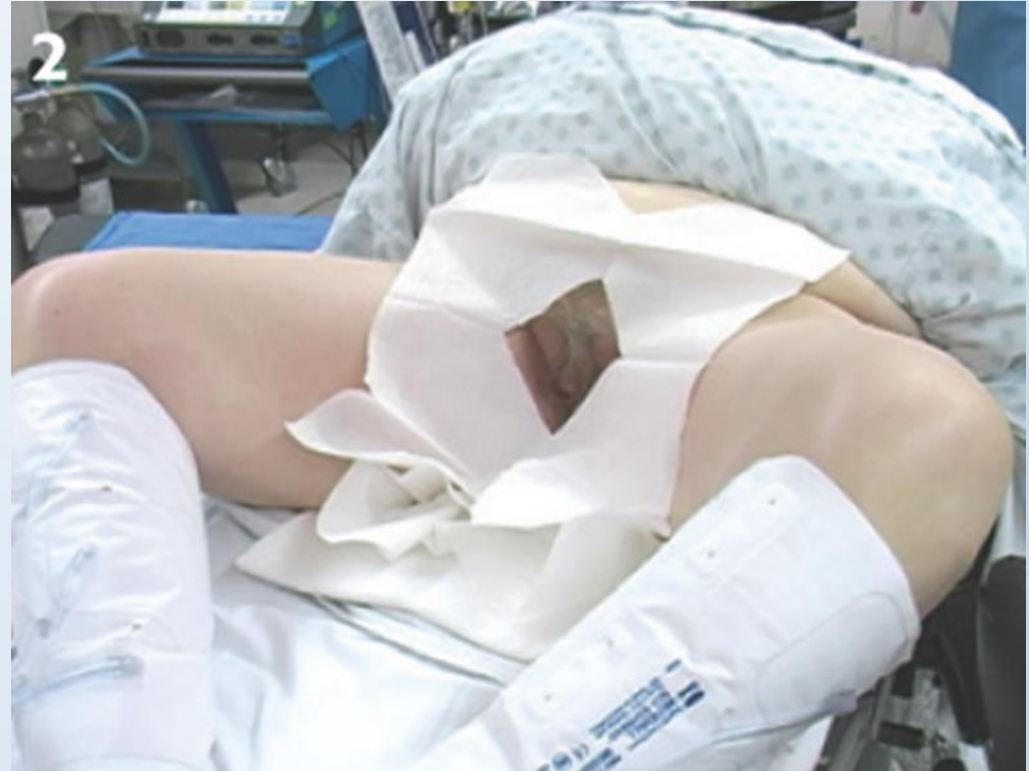

# Female Urethral Catheterization and Bladder Irrigation

Place the patient in the frog-leg position

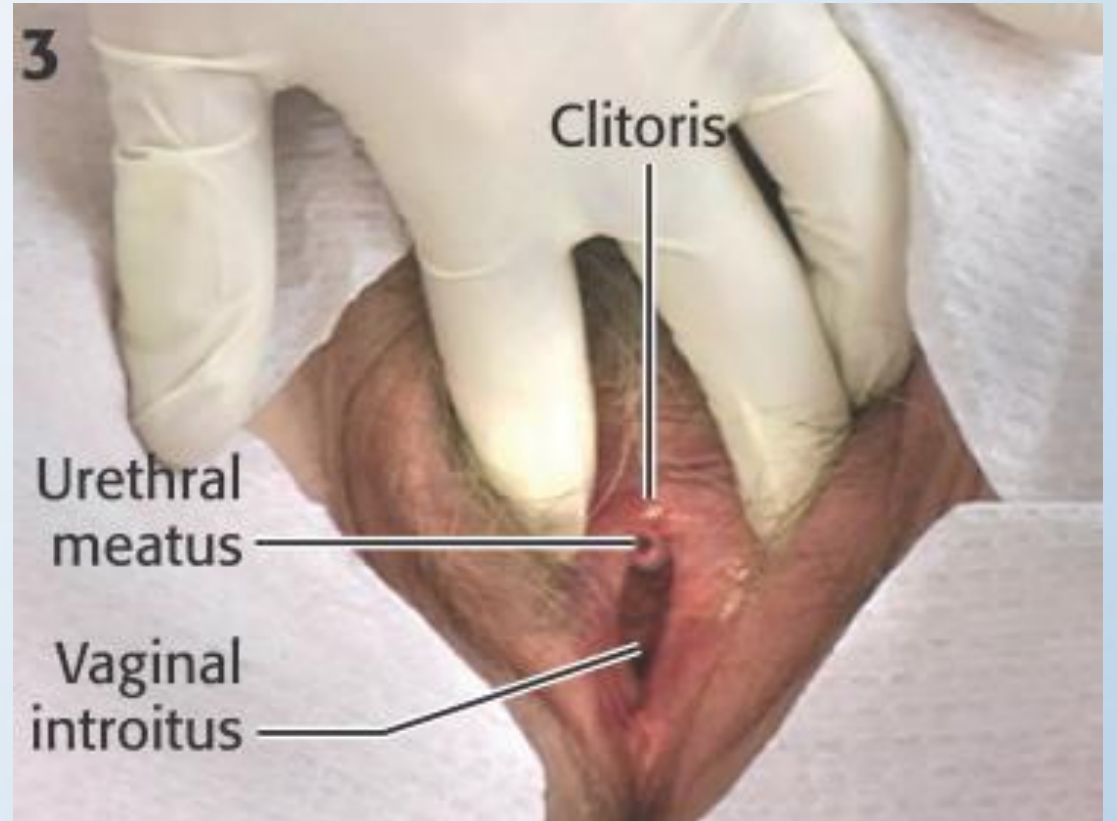

**Place a sterile fenestrated drape over the area**

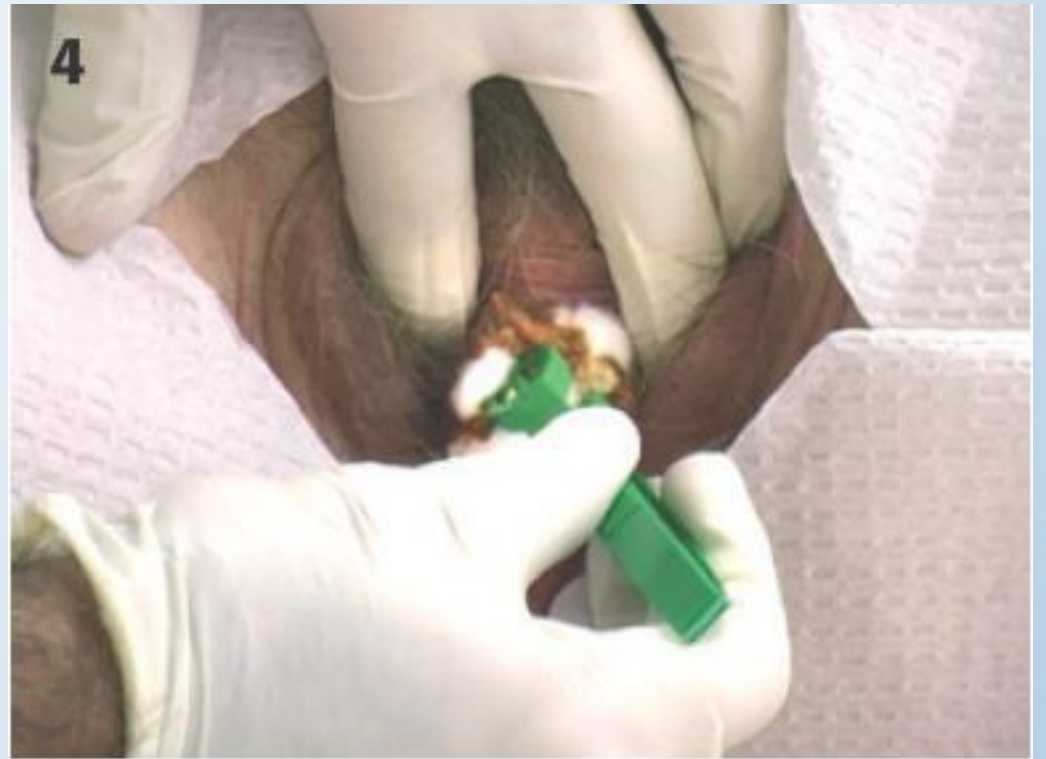



**Use your nondominant hand to spread the labia and identify the urethral meatus**

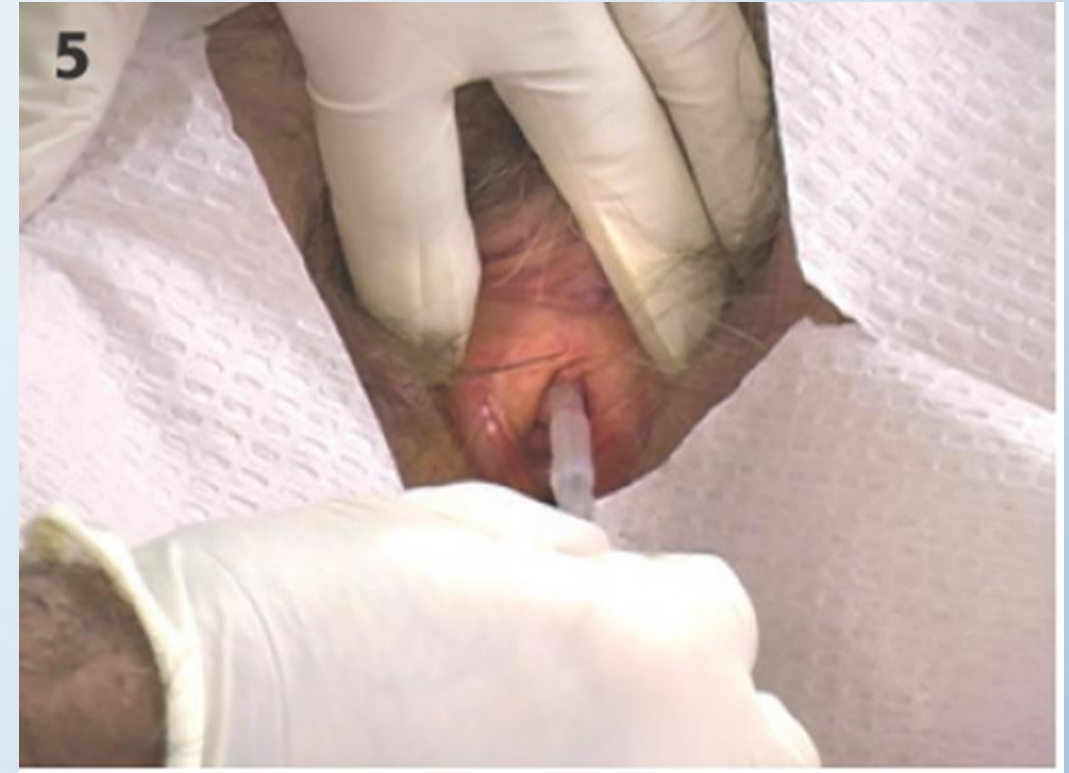

**Cleanse the urethral meatus with antiseptic in progressively increasing concentric circles**

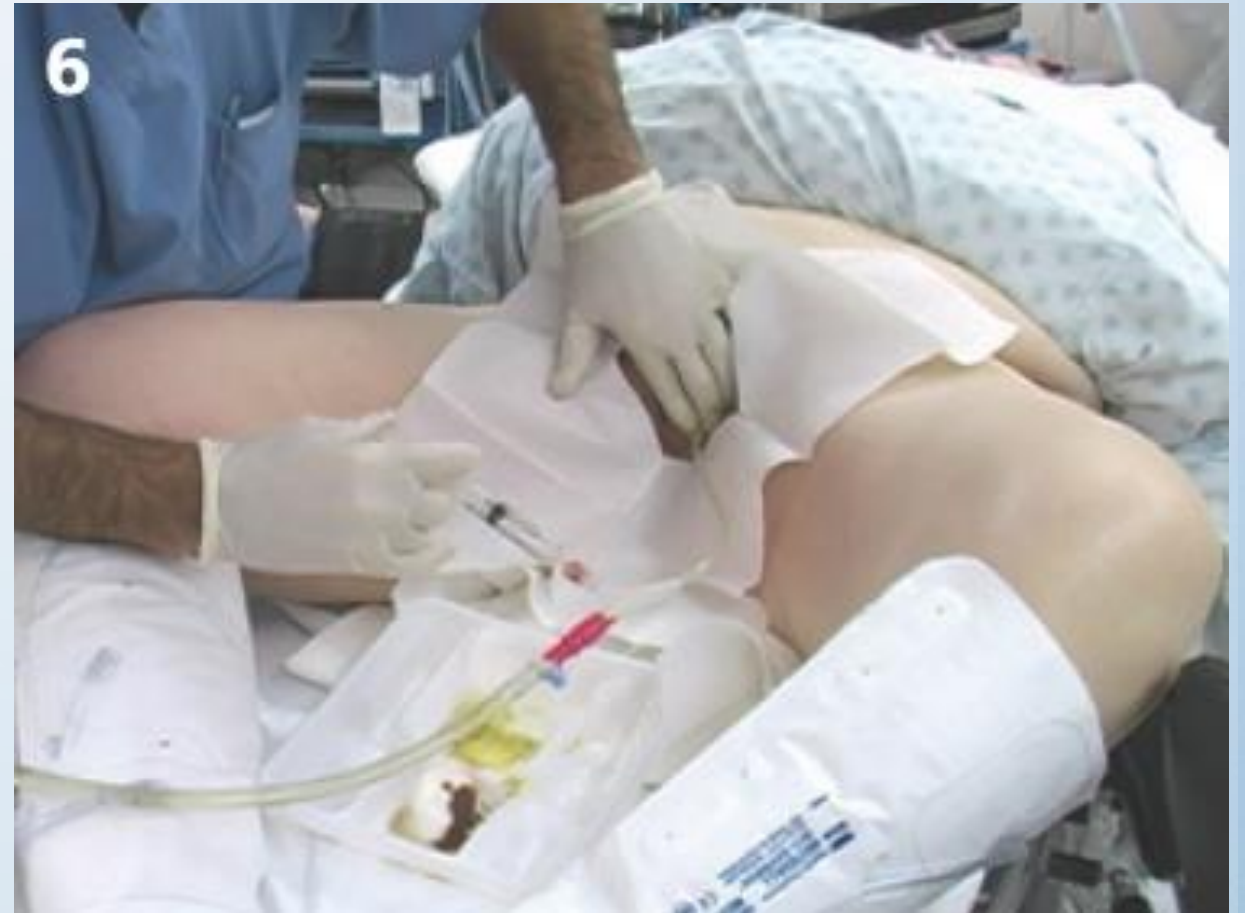

**Insert the catheter  
into the meatus  
under direct vision**

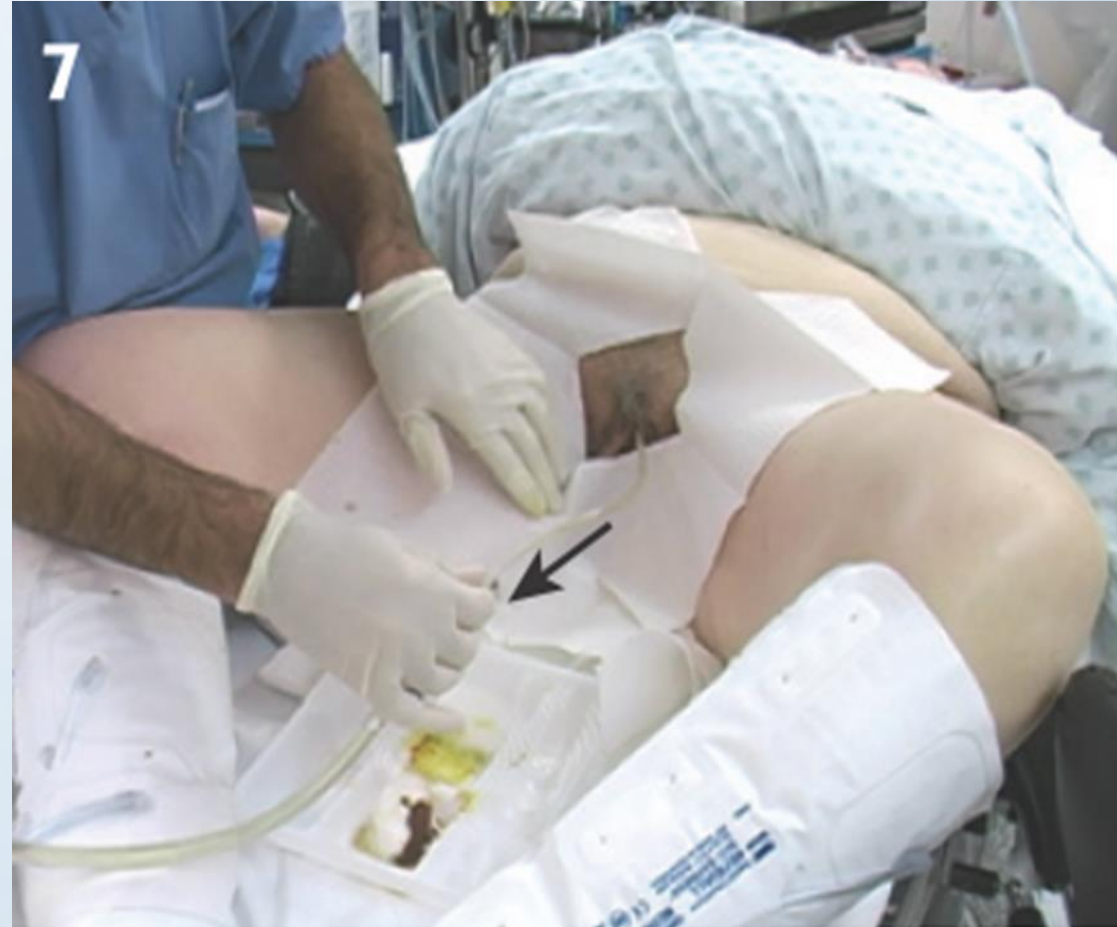If the catheter accidentally enters  
the vagina, it should  
be discarded



Once the catheter is in bladder and **urine returns** , advance catheter several cm farther and **inflate the balloon** with water or air.

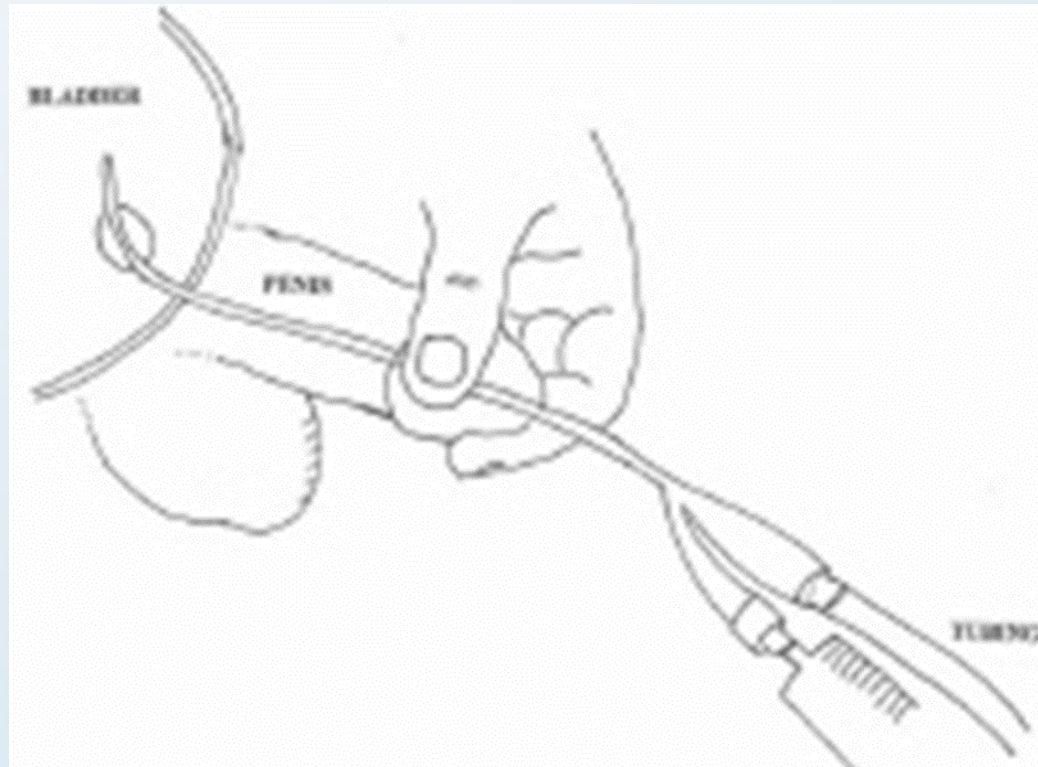


**Gently retract catheter** until balloon encounters bladder neck and resistance is felt



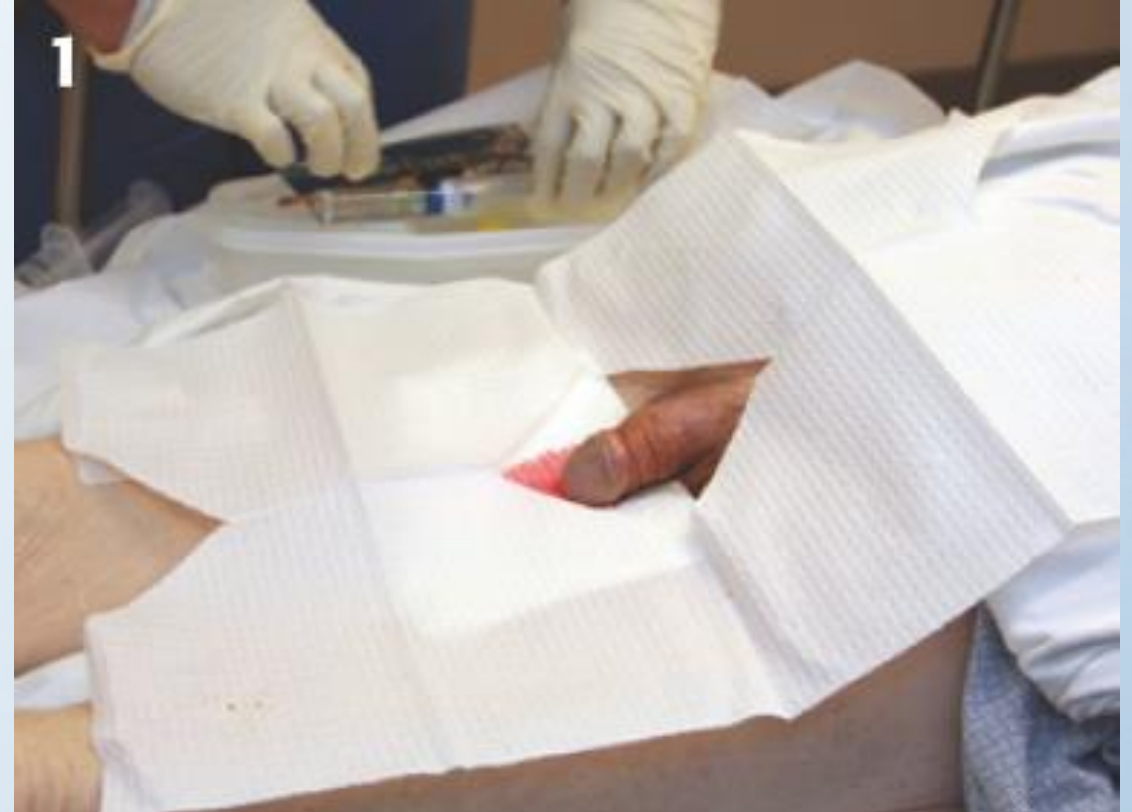

# Male Urethral Catheterization



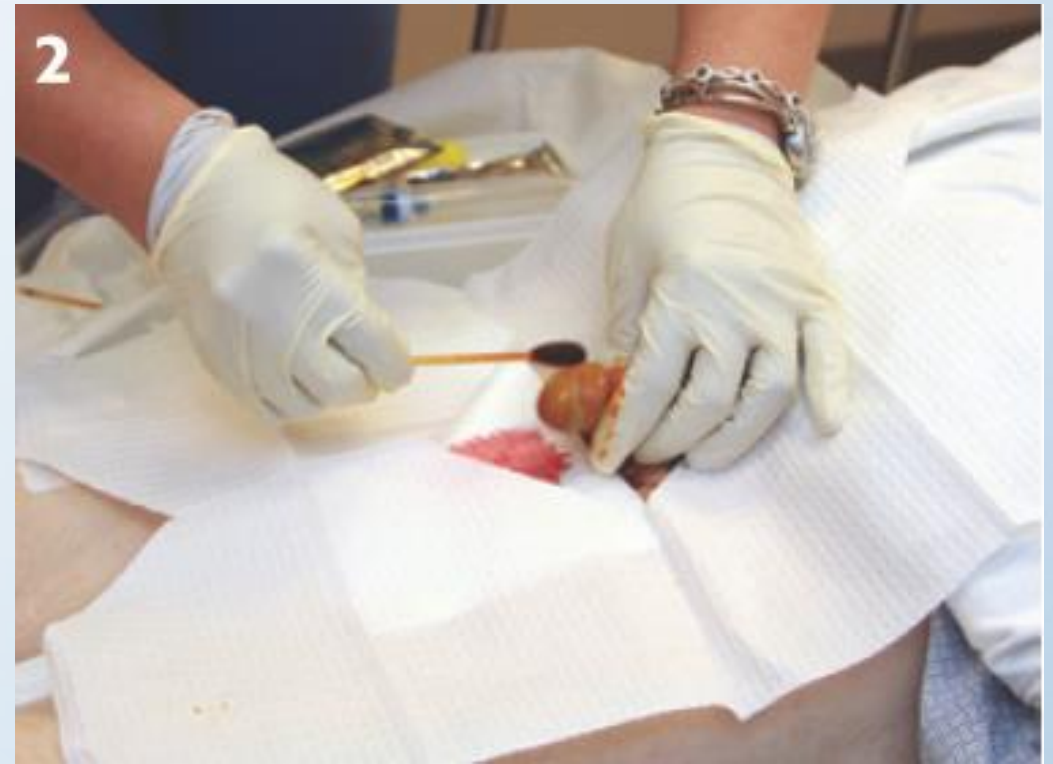# Male Urethral Catheterization and Bladder Irrigation

- Prepare your equipment
- Place a sterile fenestrated drape around penis.
- If the patient is uncircumcised, retract foreskin prior to the procedure



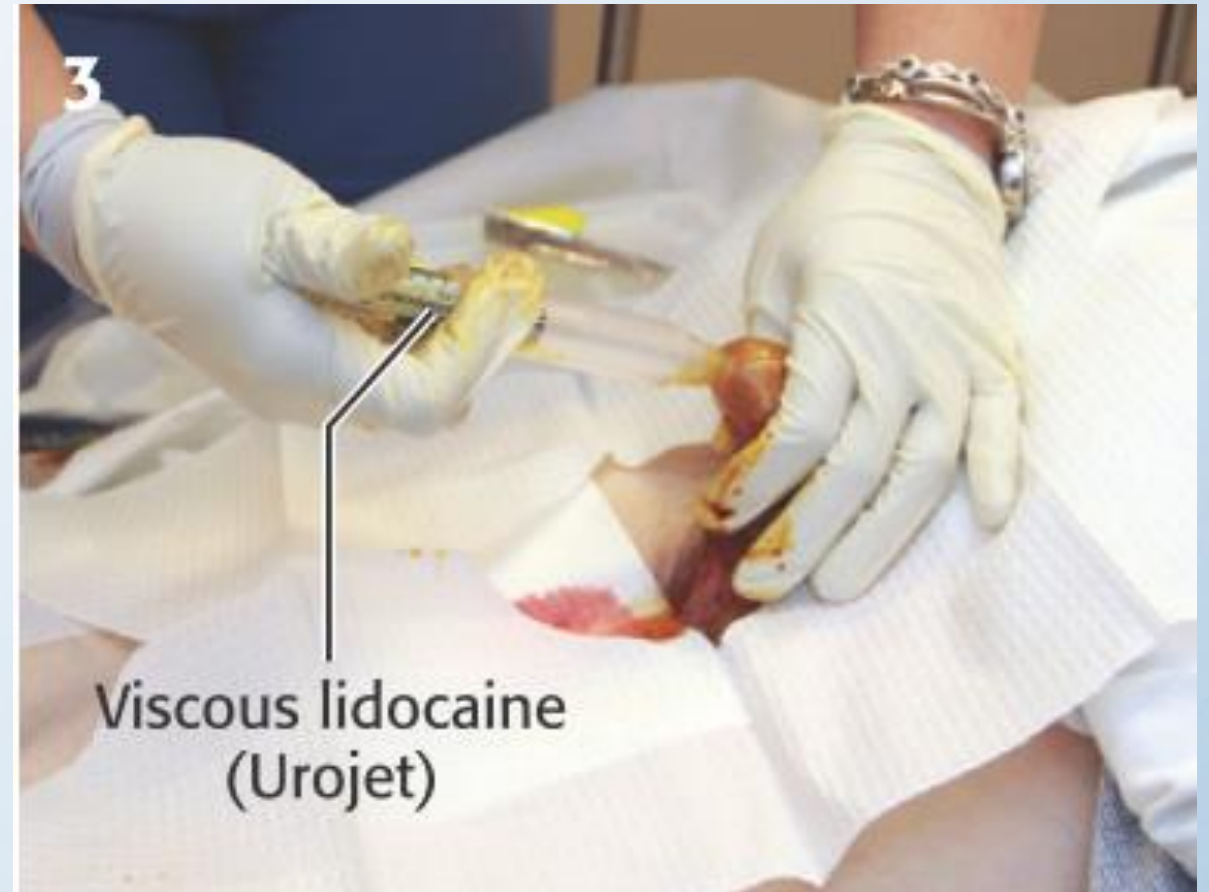
**Use your nondominant hand to hold the penis, and cleanse the meatus and surrounding tissue with antiseptic.**

Your nondominant hand is now contaminated

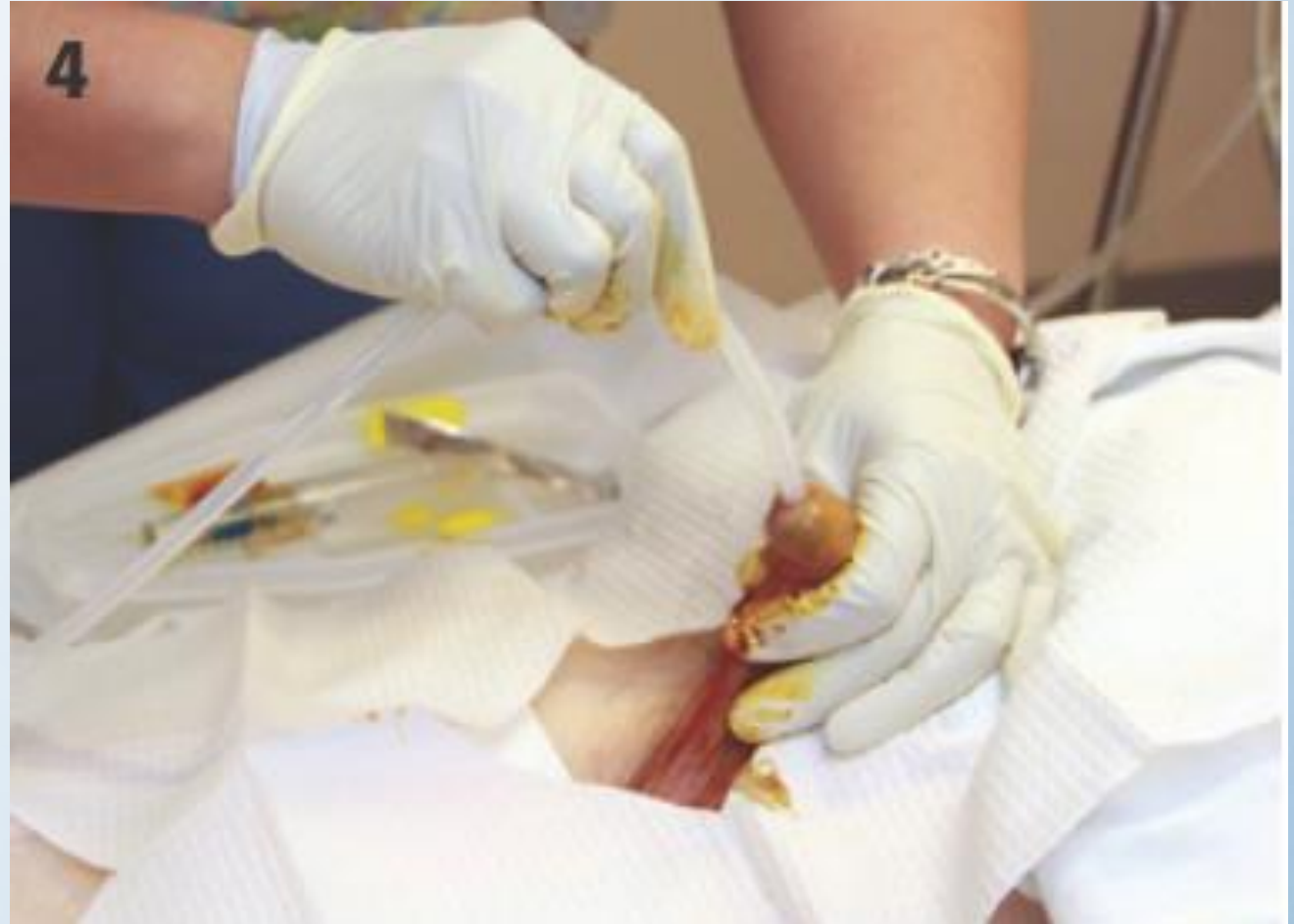

**Inject the urethra with 5-10 mL 2% lidocaine to distend urethra and provide topical anesthesia.**

*If possible, wait 5 -10 min for maximum anesthetic effect.*



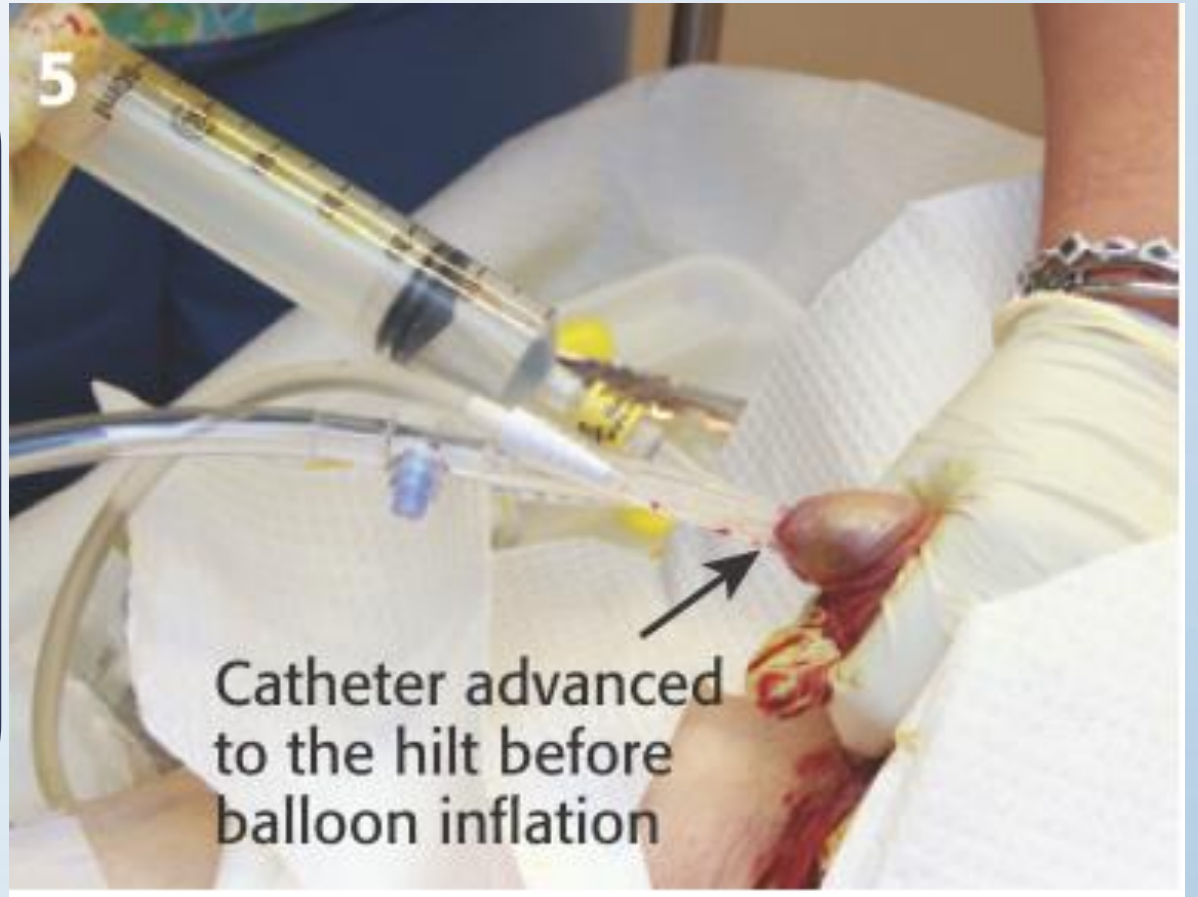**Hold the penis and upright**  
with your  
nondominant hand while  
you pass the catheter into  
the urethra





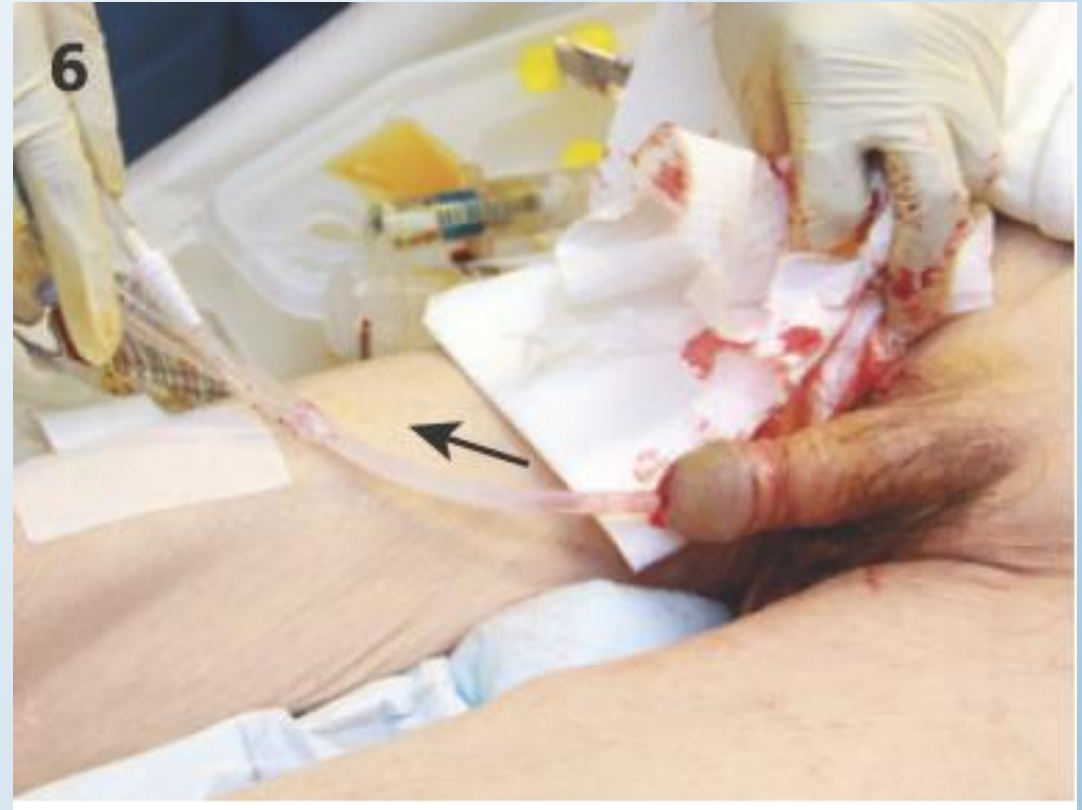**Advance the catheter  
Before inflating the balloon**  
with air or water.

If there is obvious resistance or patient discomfort, immediately deflate and reevaluate position of catheter.

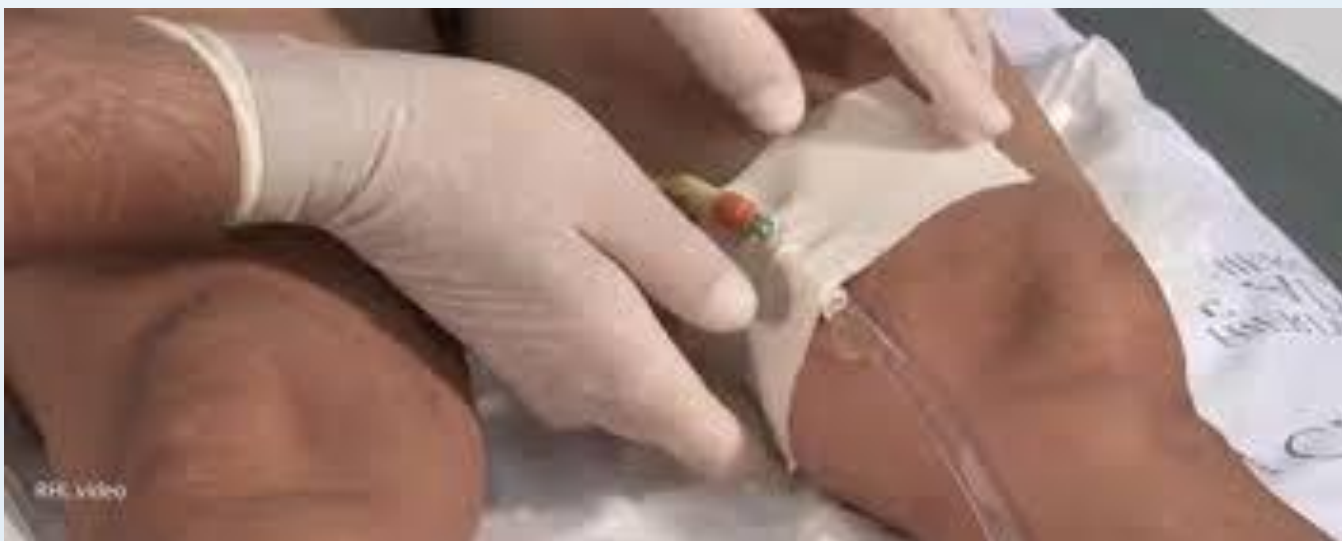

After balloon inflation, **slowly withdraw catheter** until balloon is against the bladder neck and precluding further withdrawal.

Connect to a drainage system if one is not preattached



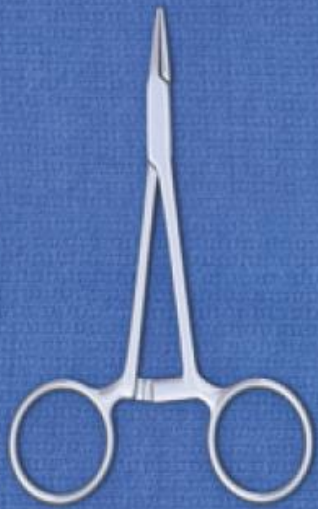## Fix the catheter



# Wound Management



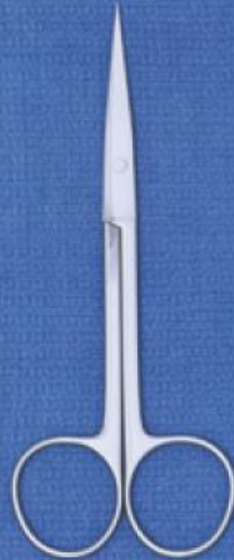# Equipment



Needle driver



Forceps

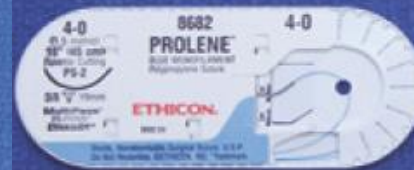

Suture scissors

## Nonabsorbable



Nylon monofilament



Polypropylene monofilament

## Absorbable



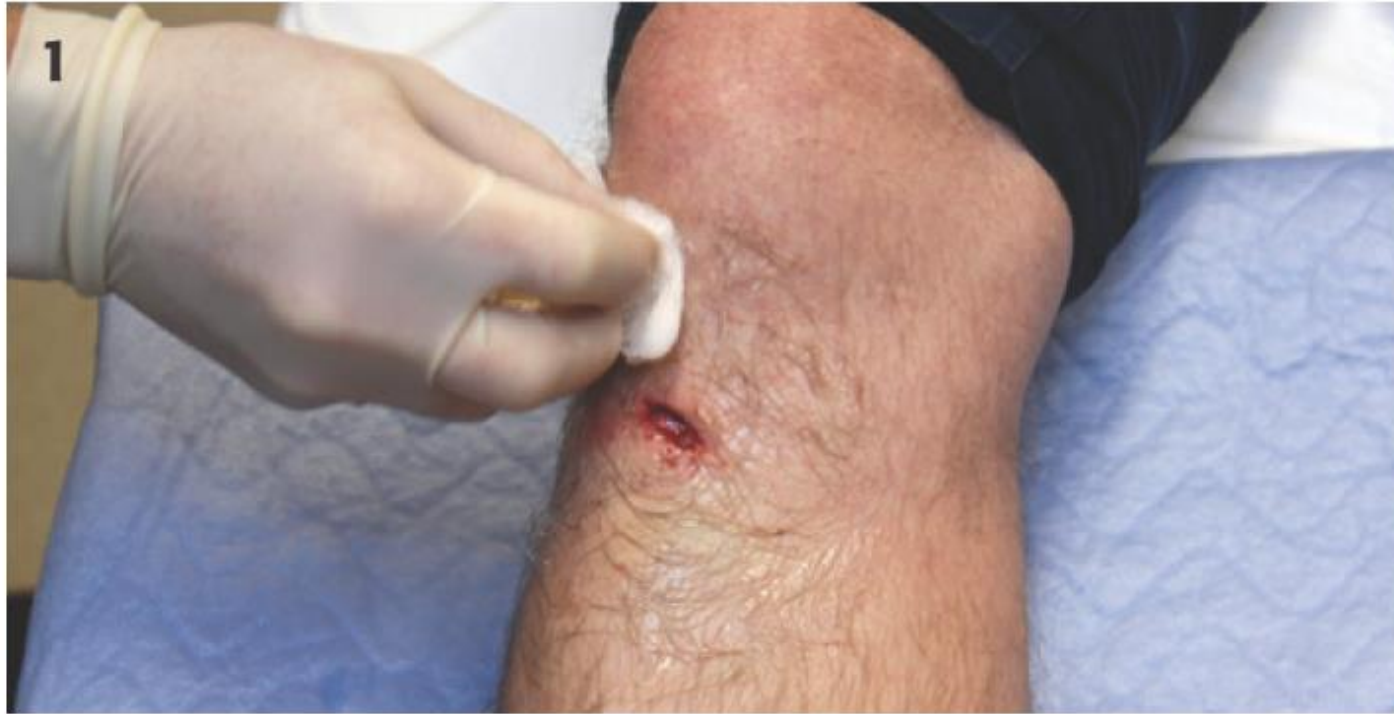Plain gut monofilament



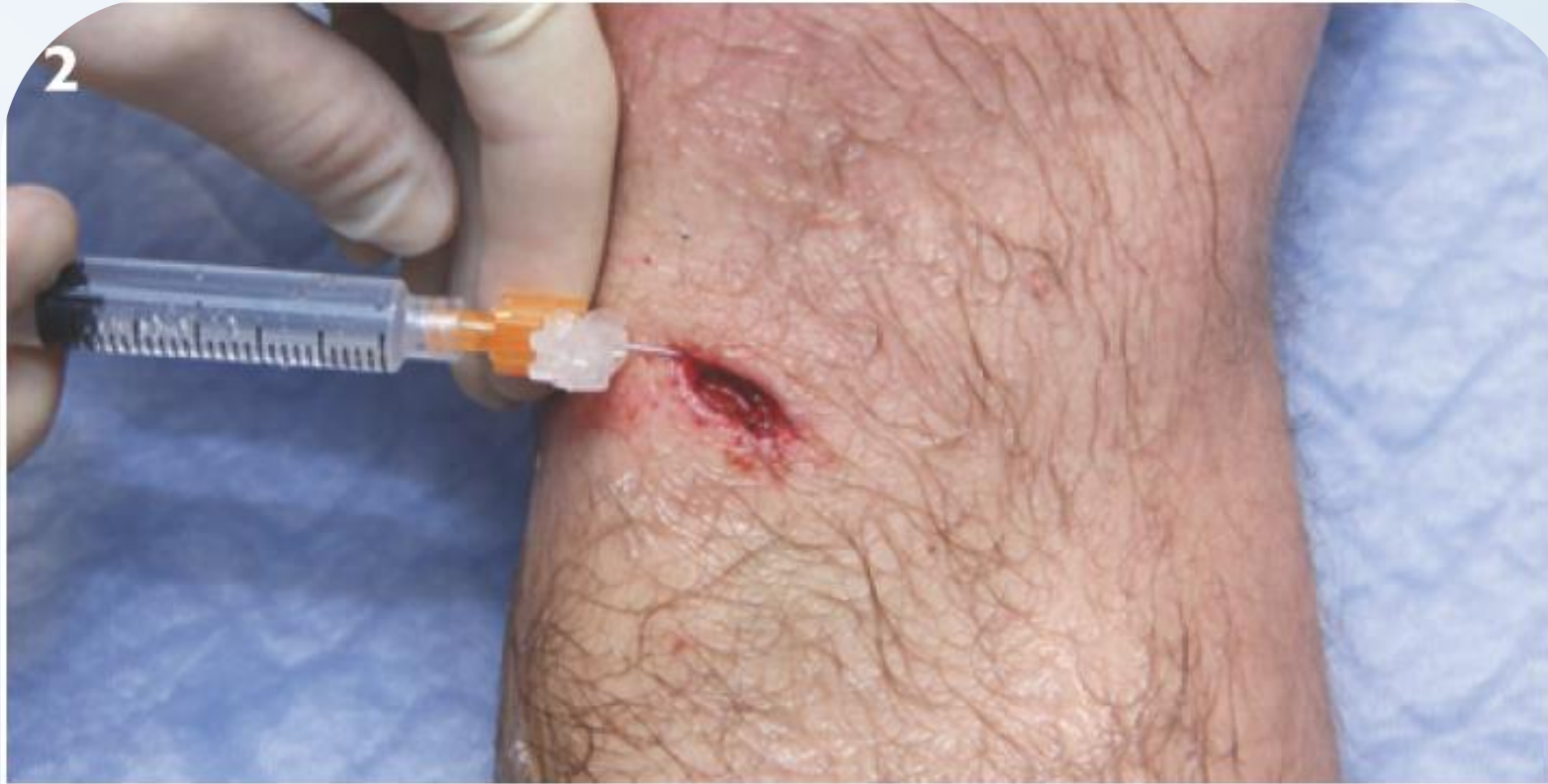Vicryl (polyglactin) multifilament



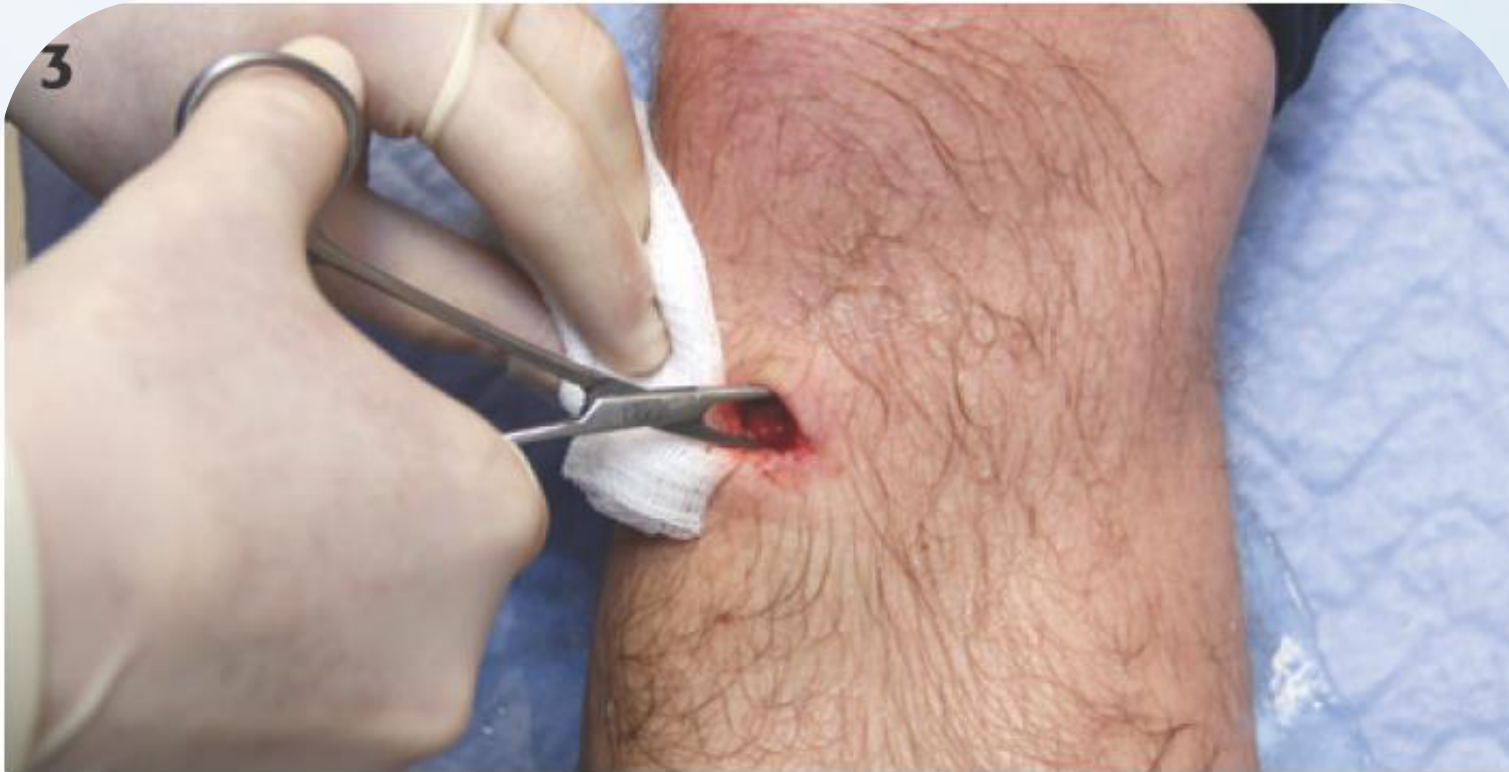# General Suturing Technique



Cleanse the skin surrounding the wound with an antiseptic such as chlorhexidine or povidone-iodine. Avoid introducing antiseptic into the wound because it may be toxic to tissue.

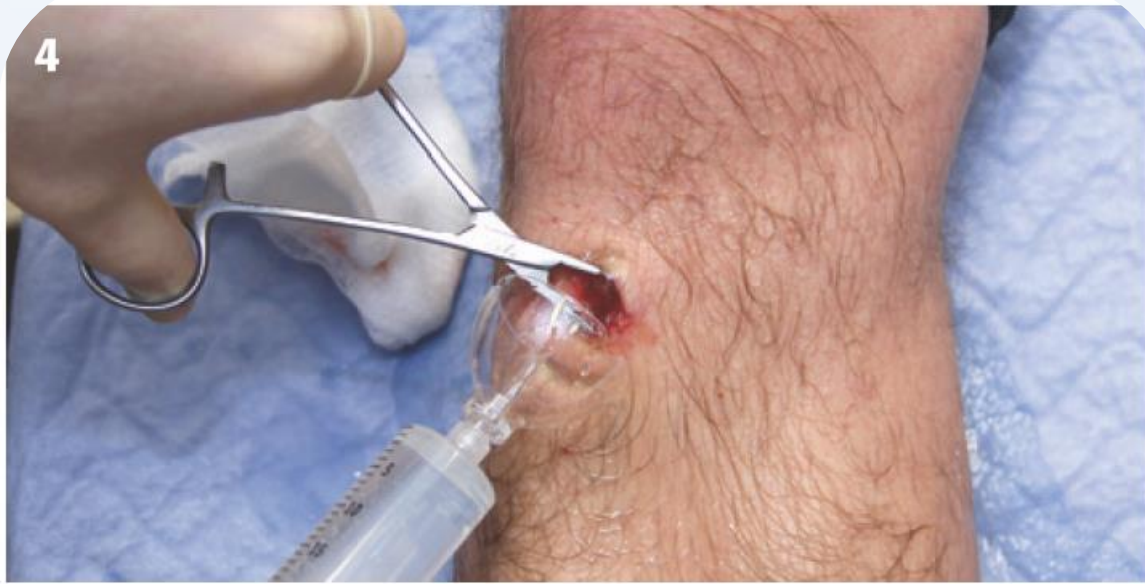

2  
Anesthetize the wound prior to exploration and irrigation.  
Introduce the needle through the wound (as opposed to through the epidermis).

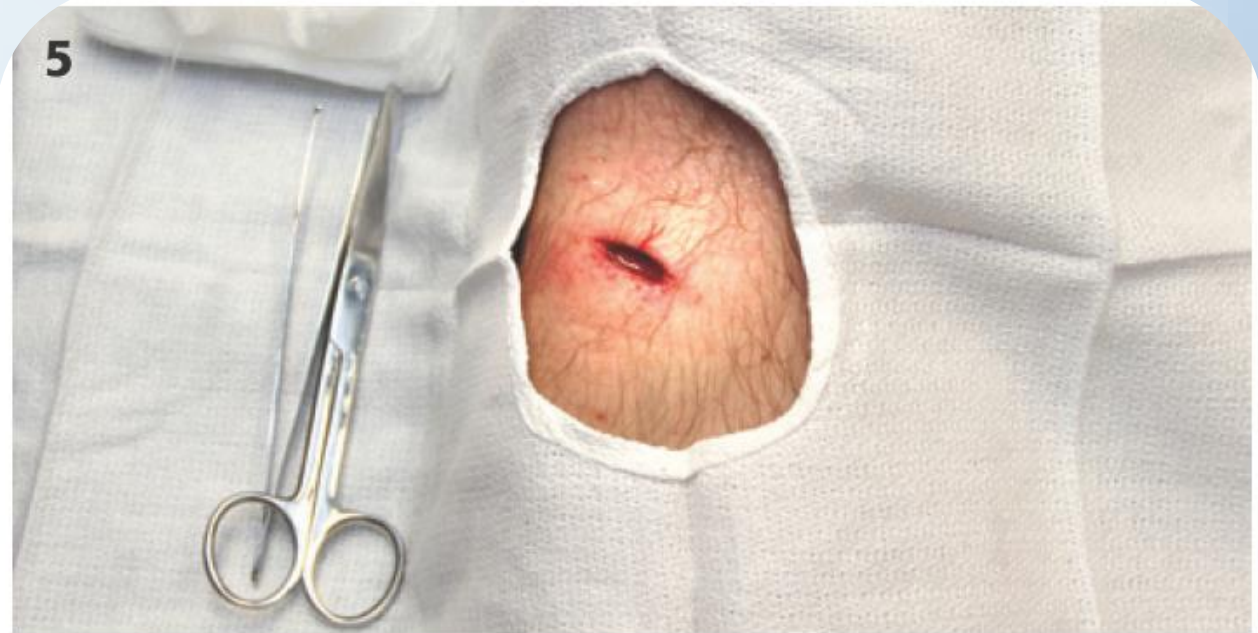

Explore the wound to exclude the presence of foreign bodies, gross contamination, or injuries to deep structures. Débride grossly contaminated or devitalized tissue.

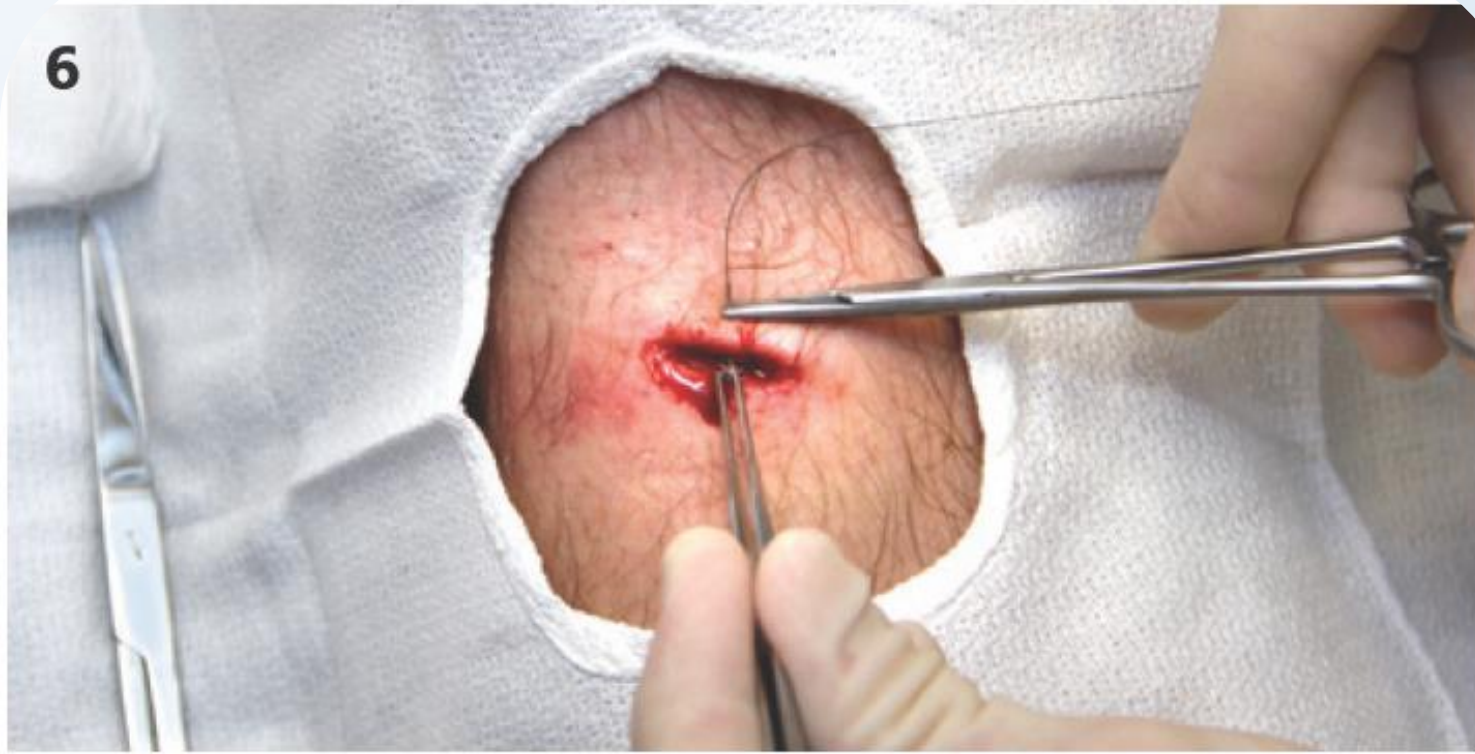



Irrigate the wound thoroughly until it is visibly clean. Use of a large syringe with a splash guard is ideal. Retract the wound edges with an instrument to facilitate thorough irrigation.

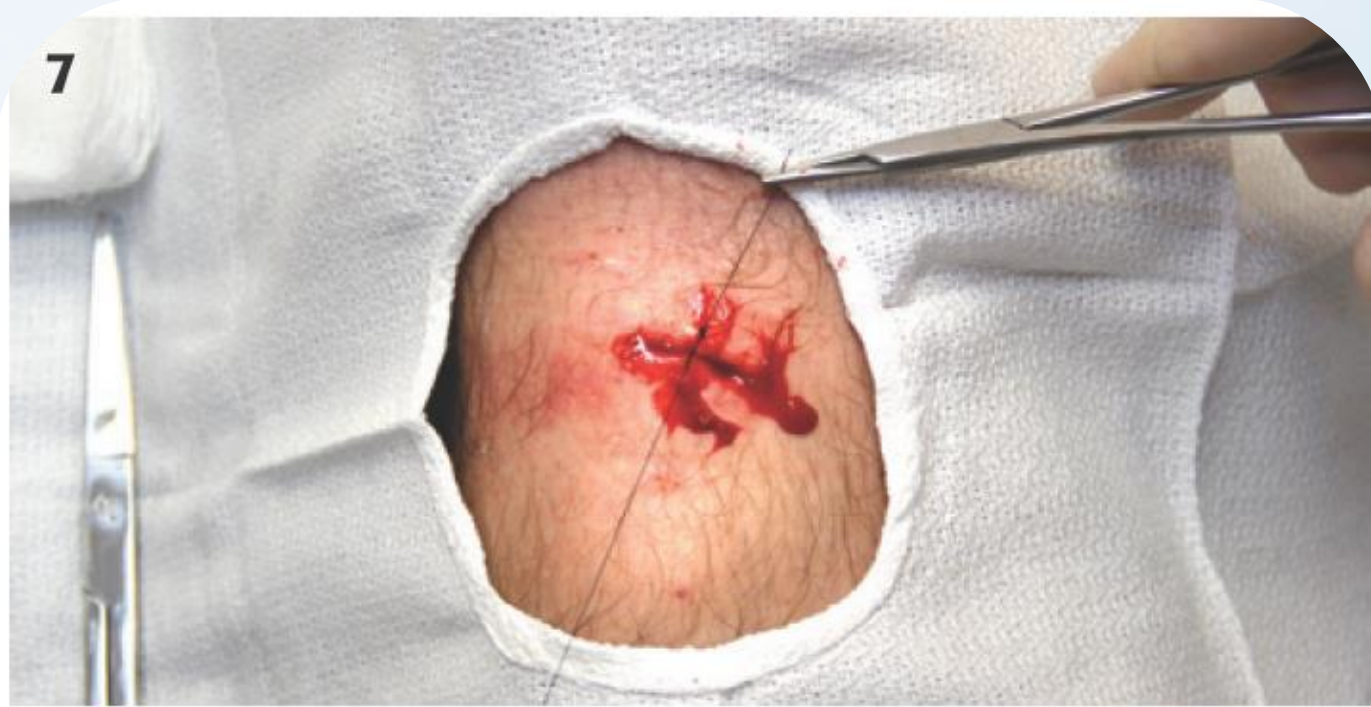

Apply a sterile drape, gather the instruments, and ensure that the field is appropriately lit.



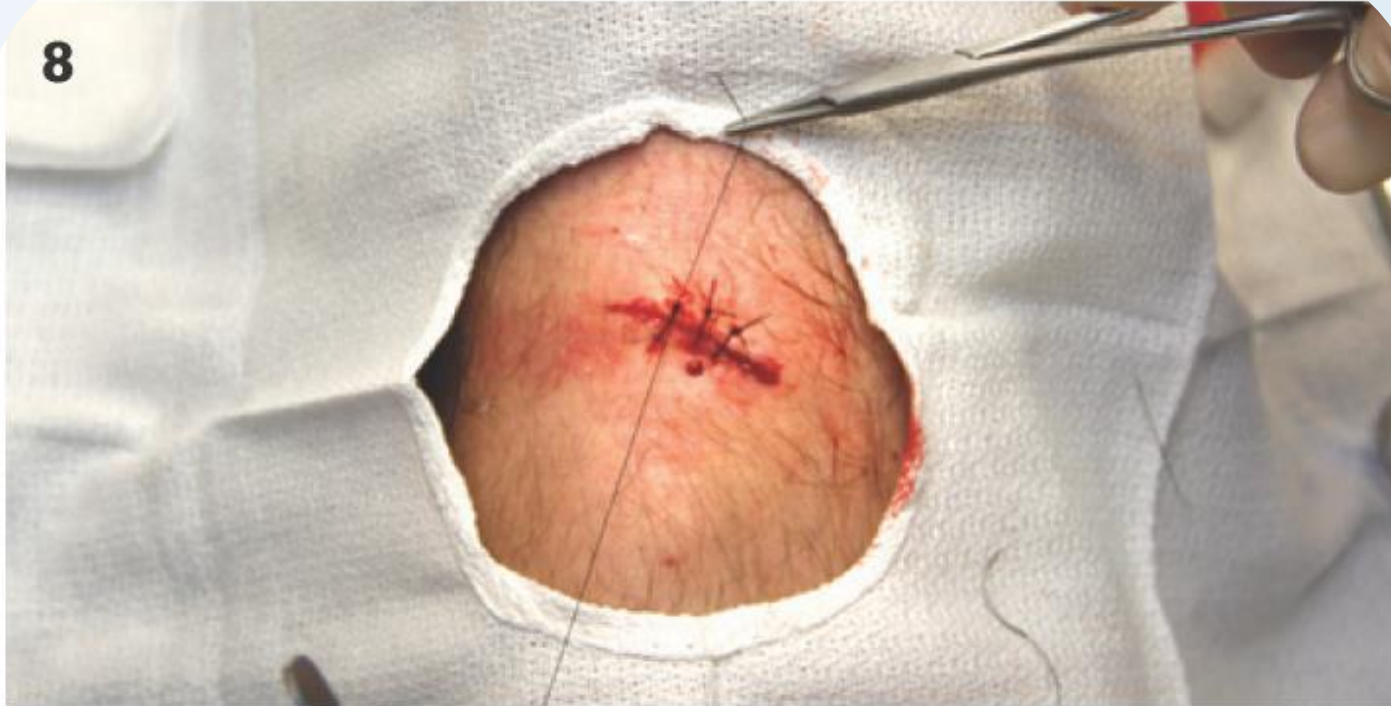Place the first suture at the center of the wound so that it bisects the laceration into two equal segments.



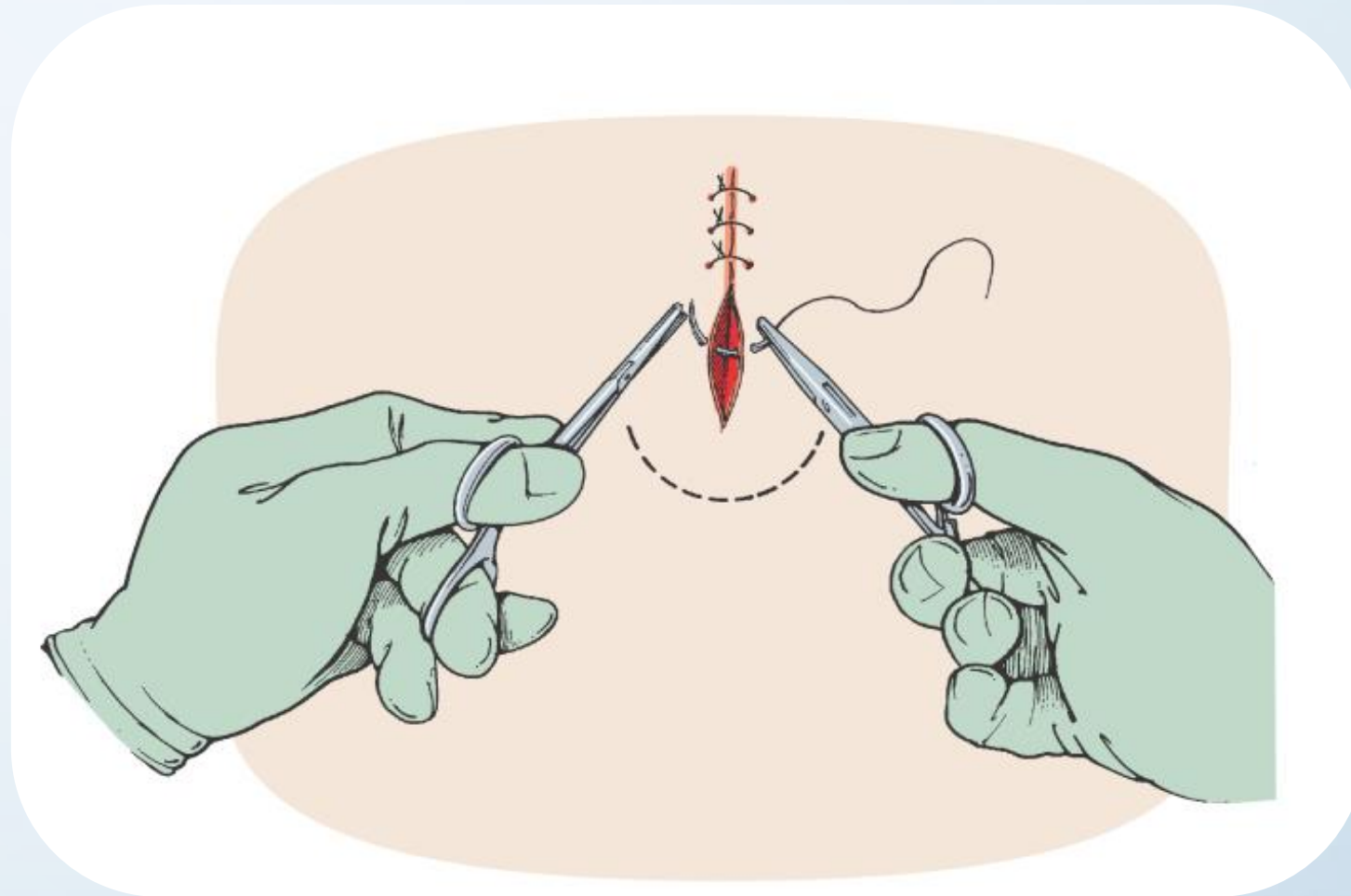


Tie the knot. The first throw should be a double throw (i.e., surgeon's knot) to prevent it from loosening. Place an additional three (single) throws and then cut the sutures while leaving to 2-cm tails.

8



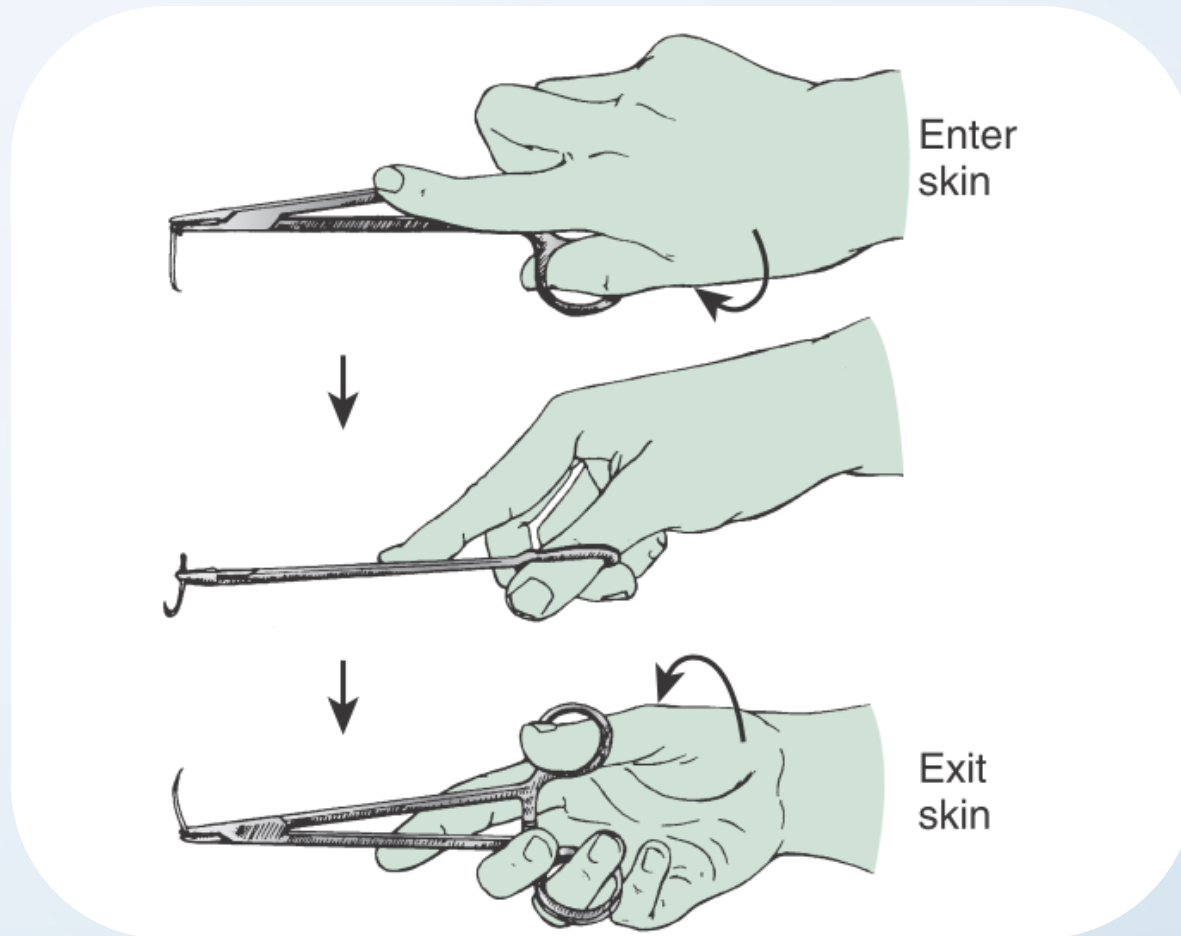
Continue to place additional sutures by further bisecting each segment of the laceration. After the last stitch has been placed, cleanse the area and apply an appropriate dressing.



The needle should be large enough to pass through tissue and should exit far enough to enable the needle holder to be repositioned on the end of the needle at a safe distance from the point



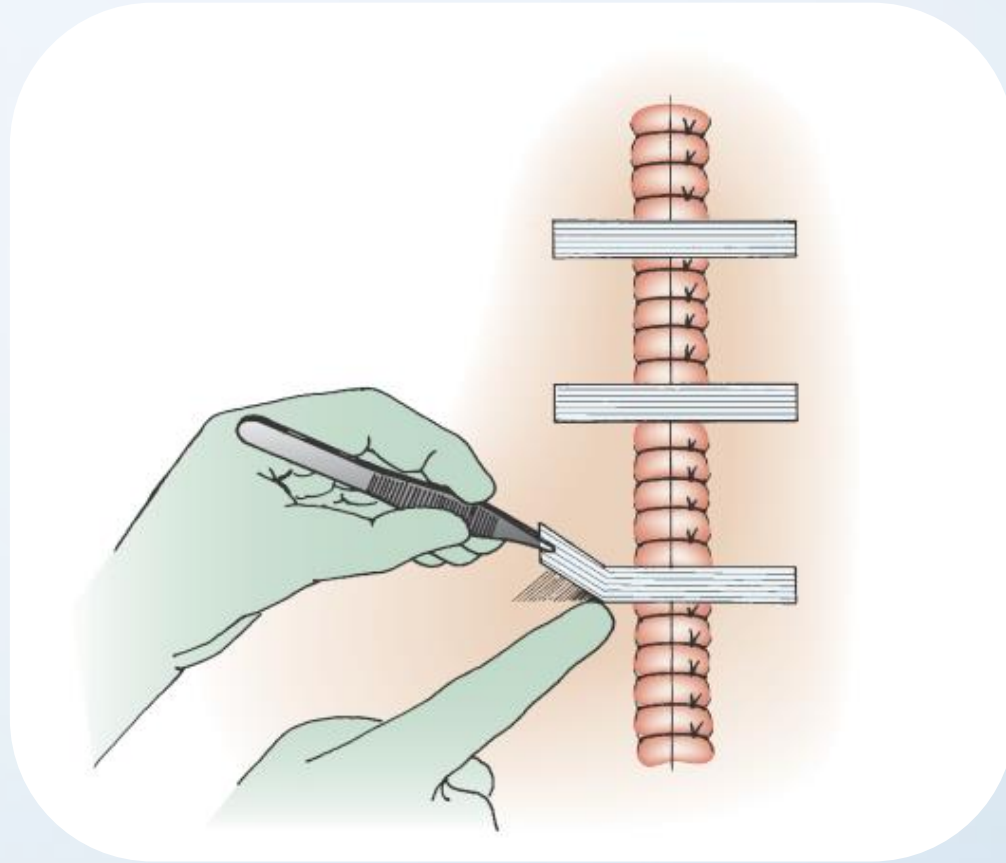
In most situations, the needle should be loaded perpendicular to the needle driver



Motion of the needle holder mimics the curve of the needle

Rotate the wrist (pronate) so that the needle enters the skin perpendicularly, not at an angle, as the wrist supinates





Wound closure tape can be used to provide additional support while sutures are in place and after they are removed

**Thank You For Your Attention**